







Myomectomy During the First and Second Trimesters of Pregnancy. A Therapeutic Dilemma: Report of Two Cases

Hamidou Soumana Diaouga¹ , Maimouna Chaibou Yacouba¹ , Rahamatou Madeleine Garba¹ ,
Maina Oumara² , Nafiou Idi³ , Madi Nayama¹ 

¹Abdou Moumouni University, Department of Obstetrics and Gynecology, Issaka Gazobi Maternity in Niamey, Niger

²Abdou Moumouni University, Department of Obstetrics and Gynecology, General Reference Hospital in Niamey, Niger

³Abdou Moumouni University, Department of Obstetrics and Gynecology, Maternity of the Regional Hospital of Niamey, Niger

Correspondence to: Hamidou Soumana Diaouga; email: hamidousoumana21@gmail.com

Received: 12 Jul 2023; Revised: 10 Nov 2023; Accepted: 11 Nov 2023; Available online: ***

Summary

Myomectomy during pregnancy is a rare situation, reserved for exceptional cases. We report two cases of myomectomy during pregnancy. Case 1 was a 31-year-old primigravida with a large transmural myoma complicated by intense pelvic pain not responding to medical treatment due to red degeneration in a 6-week pregnancy. Case 2 was a 30-year-old primigravida with multiple myomas complicated by necrosis and hydronephrosis. We performed multiple myomectomy at 17 weeks' pregnancy after failure of medical treatment. Concerning the operative technique, we performed myomectomy during pregnancy followed by prophylactic cerclage of the cervix. The operation is carried out as quickly as possible by the most experienced surgeon of the team, in order to shorten the operating time and limit blood loss. Myomas that are in contact with the uterine cavity are not removed. In all, 500mg of hydroxyprogesterone was administered intramuscularly 24h before the procedure, intraoperatively, and after operation to limit the risk of abortion. In Case 1, myomectomy was performed

successfully without maternal or fetal complications. However, the patient developed placental abruption at 33 weeks of pregnancy. The newborn died 3h after birth. In Case 2, myomectomy was complicated by a spontaneous abortion at the end of the operation. The patient developed necrosis of the remaining myomas and endometritis leading to hysterectomy. Thus myomectomy during pregnancy should be performed as a last resort in only well-selected patients.

Keywords: Leiomyoma, Myomectomy in pregnancy, Pregnancy

Ann Afr Surg. 2024; 21(1): **-**

DOI: <http://dx.doi.org/10.4314/aas.v21i1.2>

Conflict of interest: None

Funding: None

© 2024 Author. This work is licensed under the Creative Commons Attribution 4.0 International License.

Introduction

Myomectomy during pregnancy is a rare situation reserved for conditions such as the torsion of

pedunculated myomas, cases of necrosis, resultant inflammatory peritoneal reaction, and failure of medical

treatment (1–5). Myomectomy during pregnancy has been discussed since over a 100 years ago (4, 6). Traditionally, it has been discouraged because of a high risk of life-threatening hemorrhage, miscarriage, and preterm delivery. The hemorrhage may be severe enough to even result in hysterectomy (1). Hemorrhage should be the first and most dreaded complication. More recent studies are less alarmist and allow this surgery in carefully selected patients (2–12). These are mainly serious maternal complications such as intense pelvic pain not responding to conservative management due to necrosis or the torsion of a pedunculated myoma, the rapid increase in the volume of myoma, or even the occurrence of compression of the intra-abdominal organs leading to high maternal morbidity and mortality (4). In this situation, the management of myoma is a real therapeutic dilemma. We report our experience on myomectomy during early pregnancy in two patients. We describe the therapeutic difficulties and the maternal and fetal outcomes in a center with limited resources.

Case presentation

Case 1

Clinical presentation

A 32-year-old primigravida, with no medical or surgical comorbidities, was admitted to our department for intense pelvic pain evolving for 4 days in a 6 week + 3 day pregnancy. In her history, she had been followed for more than 10 years in other centers for primary infertility. This pregnancy had occurred spontaneously and was for her an unexpected opportunity to be a mother. On admission, the obstetrical examination found a uterus corresponding to the size of a 28-week pregnancy. The abdomen was tender on palpation. Vaginal examination revealed a globular uterus with a long and posterior cervix.

Diagnosis assessment

Urgent pelvic ultrasound showed an evolving single fetus at 6 week + 3 days pregnancy and a transmural myoma measuring 18.9 cm × 12.3 cm in size with no impact on the urinary tract. No anomalies were noted elsewhere. The biological assessment was normal. We diagnosed a large myoma in necrosis during pregnancy.

Management

A conservative management based on paracetamol 1 g/6 h and ketoprofen 100 mg/12 h was followed. Hydration with isotonic fluid was as follows: saline serum and ringer lactate at the rate 1.5 L/24 h (isotonic saline serum 500 cc/12 h and ringer lactate serum 500 cc/24 h) associated with hydroxyprogesterone 500 mg/24 h, and antibiotic therapy based on ceftriaxone 2 g/24 h was done. After 5 days, the evolution was marked by the persistence of pelvic pain, which became more intense. We discussed with the patient other alternatives, including myomectomy, giving her enlightened information on the risk of abortion, pregnancy loss, fetal injury, preterm delivery, and bleeding that could lead to hysterectomy. The patient agreed to all of these risks and gave her consent for myomectomy during pregnancy. Laparotomy approach by longitudinal skin incision was performed under general anesthesia using a midline incision that extended over the umbilicus. Intraoperatively, a voluminous intramural myoma located at the uterine fundus was discovered. A myoma 20 cm × 12 cm in size was removed. Reconstruction of the uterine wall was carried out using a two-layer suture with vicryl 1. Hemostasis was good. We performed prophylactic cerclage of the cervix in accordance with the protocol of our service. The operating time was 53 min and the blood loss was estimated at 200 mL. The myoma weighed 2.5 kg (Figure 1).

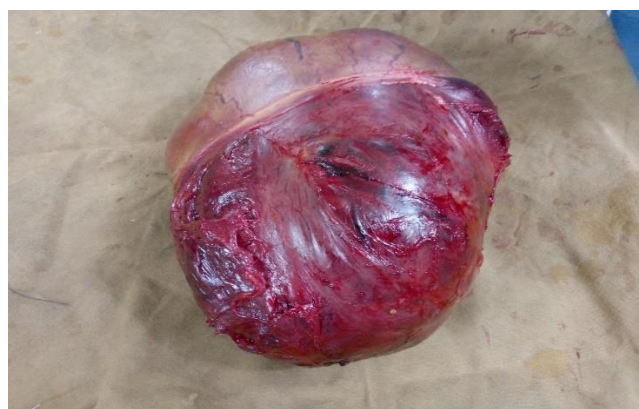

Figure 1. Piece of myomectomy in the first trimester of pregnancy; voluminous intramural fundal myoma in necrosis weighing 2.4 kg.

Complications and outcomes

The post-operative course was uneventful with disappearance of pain after the surgery. Antibiotics (ceftriaxone 2 g one time a day) and paracetamol 1 g three times a day were administered for 5 days. Hydroxyprogesterone 500 mg/24 h was continued for 15 days. An obstetrical ultrasound was performed on post-operative day 2, demonstrating good progression of the pregnancy. The patient was discharged on the tenth post-operative day in good health.

Follow-up

She was followed up every 2 weeks until 33 weeks of gestation when she had an emergency cesarean section for placental abruption. A live baby weighing 1690 g with a 6 score Apgar at 5 min of birth was delivered. The newborn developed respiratory distress and died 3 h later. The maternal prognosis was good. We gave her psychological support and information for the next pregnancy.

Informed consent

Written informed consent to publish this case and use anonymized image was obtained from the patient.

Case 2*Clinical presentation*

A 30-year-old primigravida with no medical or surgical comorbidities was referred to our department for management of myoma in a 17-week pregnancy. She had been followed for more than 10 years in other centers for primary infertility and this pregnancy occurring spontaneously was for her an unexpected opportunity to be a mother. She complained of severe abdominal pain. Vaginal examination revealed a long posterior and closed cervix.

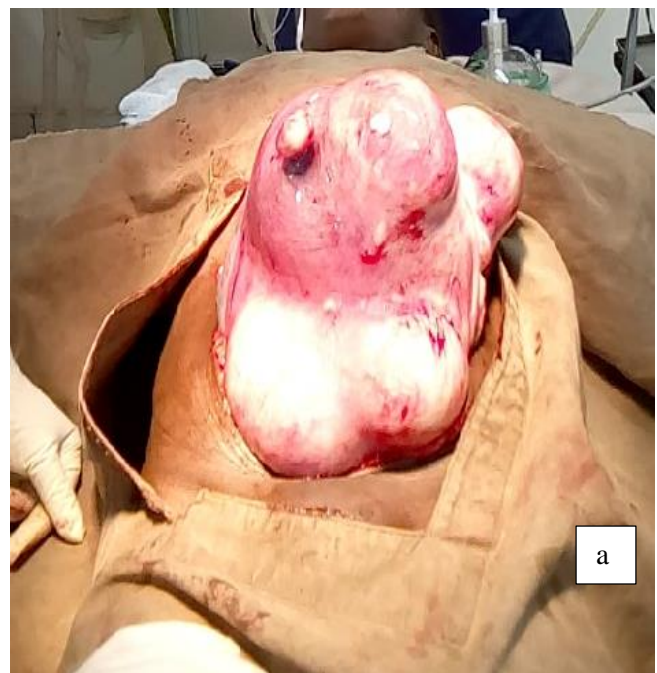
Diagnostic assessment

The abdominopelvic ultrasound showed multiple myomas, including an anterior isthmian myoma 8.9 cm × 6.4 in cm size with compression of the urinary tract, resulting in bilateral hydronephrosis. However, ultrasound did not allow us to perform the FIGO (The International Federation of Gynecology and Obstetrics)

classification of the myomas. There was no element of pyelonephritis.

Management

Conservative management was ineffective on pelvic pain and on hydronephrosis after 5 days. We discussed with the patient about the therapeutic termination of pregnancy as well as the myomectomy with its risks. The patient refused therapeutic termination of pregnancy and agreed to myomectomy during pregnancy. She agreed to the risk of abortion, pregnancy loss, fetal injury, preterm delivery, and bleeding that could lead to hysterectomy. Laparotomy approach by longitudinal skin incision was performed under general anesthesia using a midline incision. Intraoperatively, multiple intramural myomas were discovered as follows: five myomas in the posterior wall of the uterus, three myomas in the anterior wall, two located at the uterine fundus, one myoma in the lateral wall of the uterus, and other small intramural myomas (Figure 2). We removed eight myomas (four in the posterior wall, two in the anterior wall, and two in the uterine fundus). The myomas located in the lateral wall of the uterus, the isthmian myoma, and the other myomas near the uterine cavity were not removed.



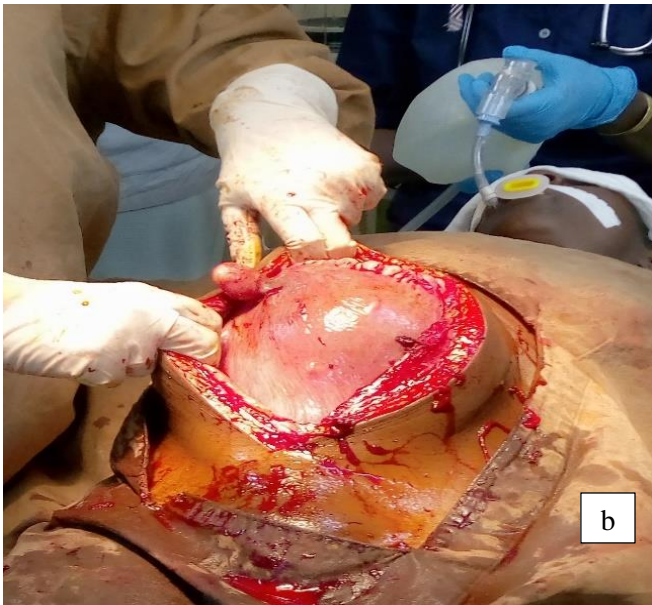


Figure 2. Myomectomy during pregnancy. (a) Intraoperative image of multiple myomas in a 17-week pregnancy. (b) Image after myomectomy and uterine wall reconstruction.

Reconstruction of the uterine wall was carried out using a two-layer suture with vicryl 1. Hemostasis was good. The operating time was 70 min and the blood loss was estimated at 350 mL.

Complications and outcomes

The post-operative course was marked by spontaneous abortion at the end of the operation (Figure 3).

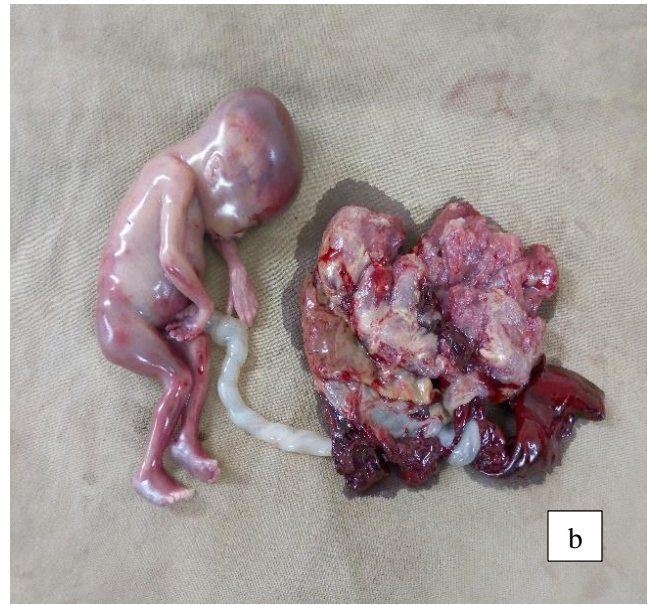

Figure 3. (a) Specimens of eight myomas removed in the second trimester of pregnancy. (b) Spontaneous abortion at the end of the operation.

Additional aspiration for uterine vacuity was performed. Antibiotics (ceftriaxone 2 g one time a day) and paracetamol 1 g three times a day were administered for 5 days. The evolution was marked on post-operative day 3 by the occurrence of intense pelvic pain not relieved by the usual analgesics associated with metrorrhagia of blackish blood.

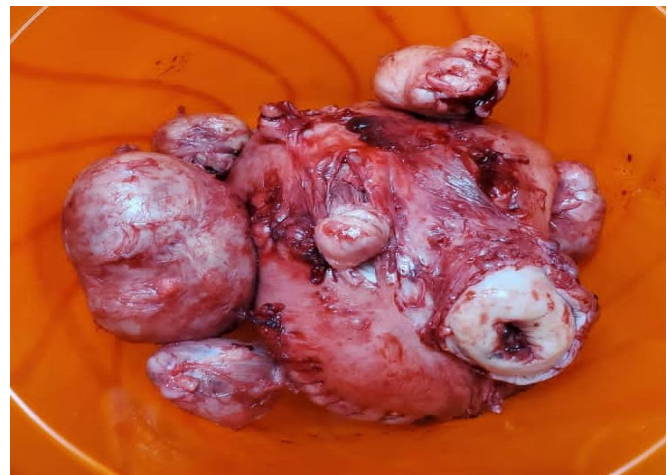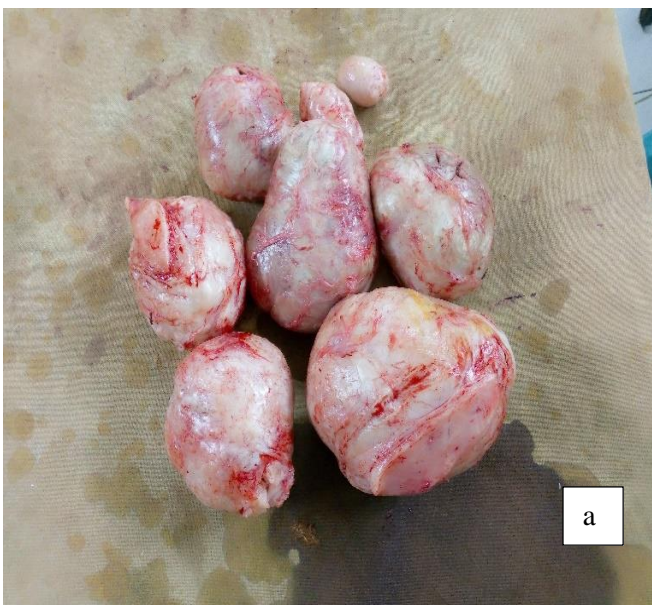


Figure 4. Specimens of hysterectomy for post-operative complication of myomectomy during pregnancy. The remaining myomas in necrosis were removed preoperatively before hysterectomy.

A decision for emergency relook laparotomy was taken. At the opening of the abdominal cavity, after aspiration of 300 mL of hemoperitoneum, we discovered a large and soft uterus with necrosis of the remaining myomas. After removal of six myomas in necrosis, a decision for total hysterectomy with preservation of the adnexa was made intraoperatively (Figure 4). The post-operative course was uneventful.

Follow-up

The patient was discharged on the 7th post-operative day in good health. She had received psychological support and a follow-up by a psychiatrist.

Informed consent

Written informed consent to publish this case and use anonymized image was obtained from the patient.

Discussion

This observation reports the therapeutic difficulties of complicated myoma in pregnancy in two primigravidae in a country with limited resources. In our patients, when symptoms persisted after 5 days of conservative management, we asked ourselves three questions. First, the question of whether medical treatment should be provided in the hope of future resolution of symptoms, was assessed. According to literature data, in cases where symptoms persist after 72 h of conservative management or torsion of a pedunculated fibroid or severe compression of other pelvic organs (as in the case of Patient 2), myomectomy may be considered if it is the second trimester, or induced abortion followed by interval myomectomy if it is the first trimester (2, 3, 5, 6, 11). Also, evidence was presented that indicated higher pregnancy losses (13.6%), premature rupture of the membranes, premature labor, and post-cesarean hysterectomy in conservatively managed women compared with those who underwent myomectomy (4, 10, 12). In all our patients, conservative management was carried out for 5 days without success.

Second, the question of medical termination of pregnancy followed by interval myomectomy later, can be an alternative. Indeed, according to literature data patients in the first trimester with symptomatic myomas

who fail to respond to conservative management may be offered induced abortion followed by interval myomectomy (2, 3). However, several cases of myomectomies performed successfully during the first trimester have been reported (2, 3, 6). Termination of pregnancy was proposed to our patients in view of our weak technical platform, but they had categorically refused. Indeed, these patients had been followed for more than 10 years in other centers for primary infertility. These pregnancies occurring spontaneously were for them an unexpected opportunity to be a mother. Third, the question of whether myomectomy should be performed during pregnancy despite the high risk of intraoperative and post-operative complications was assessed. Indeed it has been reported that if symptoms persist after 72 h of pharmacological therapy, myomectomy must be considered (2, 5, 8, 10). Multiple studies have shown that women who undergo myomectomy in the second trimester actually have better outcomes than those who opt for conservative management (3, 9). Our patients all agreed to myomectomy during pregnancy, accepting the risks of pregnancy loss, fetal injury, and hysterectomy (3). Myomectomy during pregnancy raises fears of two major difficulties. First, the hemorrhage that is sometimes difficult to manage, requiring the transfusion of large quantities of blood and which can lead to hysterectomy (5–10). There is no special measure or precautions to control perioperative blood loss when performing myomectomy during pregnancy. The literature is sparse on this subject. Some authors have proposed the injection of vasopressin into the capsule of the myoma to decrease operative blood loss (3). In our patients, hemostasis was secured by using bipolar electro-surgical devices and suture with vicryl 2/0. Indeed, myomectomy during pregnancy is done without infusion of oxytocin and with administration of hydroxyprogesterone, which is utero relaxing. These situations increase the risk of hemorrhage and abortion as in our Patient 2. In this patient, we evoked also the hypothesis that she would have presented uterine contractions and cervix modifications in the period between our last examination and the beginning of the operation. In Patient 1, the myomectomy during

pregnancy was a success. Three situations could explain the poor result in Patient 2: First, the presence of a threat of abortion which would have gone undiagnosed in the period between our last examination and the beginning of the operation. Second, the prolonged operating time of 73 min, which would increase the effects of anesthesia on the uterus. Third, the multiple myomas removed (eight myomas) requiring greater manipulation of the uterus and necrosis of the remaining myomas. However, concerning the duration of the operation, the literature reports an average duration of 53 min with extremes ranging from 20 to 150 min (2, 4, 9, 11). The impact of the operation duration on the pregnancy outcome has not been evaluated. The maximum number of myomas removed during pregnancy according to the literature data is five (2, 7, 8). In Patient 2, eight myomas were removed. In a systematic review by Spyropoulou et al. (2), including 54 studies and 97 patients undergoing myomectomy during pregnancy, five patients (5%) had an abortion after myomectomy, four following a mono-myomectomy and one after multiple myomectomy; a case of hysterectomy post-cesarian section was reported (2). Indeed after myomectomy during pregnancy, the risk of abortion occurs in 5–35% of cases (2, 6). Cavaliere et al. (9) report nine cases of myomectomy during pregnancy in Italy; in one case myomectomy was complicated by spontaneous abortion that occurred with spontaneous fetal expulsion, as in Patient 2. In the other eight cases, no maternal and fetal complications arose during or after surgical treatment and delivery occurred at full term of pregnancy (9). In Greece, Lolis et al. (10) report 13 cases of myomectomy during pregnancy and one patient aborted on the first post-operative day. They noted that in 92% of these cases, successful myomectomy was performed and the pregnancy progressed to term without further complications (10). In the review of Basso et al. (5) including 63 studies and 197 women undergoing myomectomy during pregnancy, they noted 13 cases (6.5%) of miscarriage or fetal demise happened after the myomectomy. A post-operative complication leading to hysterectomy as in Patient 2 is an exceptional event (2, 5, 9). Concerning the obstetrics outcome, we noted in our first patient a preterm delivery caused by placental

abruption. She received psychological support and information for the next pregnancy. Patient 2 underwent hysterectomy. This patient had received psychological support and a follow-up by a psychiatrist. In the recent literature, a few cases of myomectomies have been successfully performed during pregnancy with good maternal and fetal outcomes (2, 9, 12). However, most of them were one or two subserous or intramural myomas (1, 3–6, 9–12), as in the case of our first patient. These rare complications related to myomectomy during pregnancy should not cause this surgery to be abandoned when the indication is well justified. The publication of all the results, particularly the poor results of myomectomy during pregnancy, should be encouraged in order to achieve a universal management protocol.

Conclusion

According to the outcomes of our patients and the results of other studies, we conclude that myomectomy during pregnancy can be performed only in well-selected patients in a well-equipped center. Counseling should be provided prior to performing this myomectomy; the risks and benefits of myomectomy during pregnancy should be carefully evaluated and discussed with patients. The publication of all results, particularly the poor results should be encouraged in order to achieve a universal management protocol. Centers specializing in the management of myoma in pregnancy, including expert surgical and anesthesiological teams must be created to improve maternal and fetal outcomes.

Ethical consideration

Informed consent was acquired from the patients for publication of the case report.

Author contributions

HSG led in the conceptualization, data curation, Project administration, resources and in writing of the original draft. All authors equally contributed to methodology, formal analysis and review and editing the original draft.

References

1. Saccardi C, Visentin S, Noventa M, et al. Uncertainties about laparoscopic myomectomy during pregnancy: a lack of evidence or an inherited misconception? A critical literature

- review starting from a peculiar case. *Minim Invasive Ther Allied Technol.* 2015; 24: 189-94.
2. Spyropoulou K, Kosmas I, Tsakiridis I, et al. Myomectomy during pregnancy: a systematic review. *Eur J Obstet & Gynecol Reprod Biol.* 2020; 254: 15-24.
 3. Leach K, Khatain L, Tocce K. First trimester myomectomy as an alternative to termination of pregnancy in a woman with a symptomatic uterine leiomyoma: a case report. *J Med Case Rep* 2011; 5: 571
 4. Allameh Z, Allameh T. Successful myomectomy in the second trimester of pregnancy. *Adv Biomed Res.* 2019; 8: 60.
 5. A Basso, M.R Catalano, G Loverro, et al. Uterine fibroid torsion during pregnancy: a case of laparotomic myomectomy at 18 weeks' gestation with systematic review of the literature. *Case Rep Obstet Gynecol.* 2017; 4970802: 11.
 6. Jhalta P, Negi SG, Sharma V. Successful myomectomy in early pregnancy for a large asymptomatic uterine myoma: case report. *Pan Afr Med J.* 2016; 24: 228.
 7. Lee Y-E, Park S, Lee K-Y, Song J-E. Risk factors based on myoma characteristics for predicting postoperative complications following cesarean myomectomy. *PLoS One.* 2023; 18: e0280953.
 8. V Lozza, A Pieralli, S Corioni, et al. Multiple laparotomic myomectomy during pregnancy: a case report. *Arch Gynecol Obstet.* 2011; 284: 613-16.
 9. Cavaliere A.F, Vidiri A, Gueli Alletti S, et al. Surgical treatment of "Large Uterine Masses" in pregnancy: a single-center experience. *Int. J. Environ. Res. Public Health.* 2021; 18: 12139.
 10. D.E Lolis, S.N Kalantaridou, G Makrydimas, et al. Successful myomectomy during pregnancy. *Hum Reprod.* 2003;18: 1699-1702.
 11. L Domenici, V Di Donato, M.L Gasparri, et al. Laparotomic myomectomy in the 16th week of pregnancy: a case report. *Case Rep Obstet Gynecol.* 2014; 154347: 5.
 12. Pelissier Komorek A, Hamm J, Bonneau S, et al. Myoma and pregnancy: When medical treatment is not sufficient. *J Gynecol Obstet Biol Reprod (Paris)* 2012; 41: 307-10.