

# Surgical management of unilateral lower limb lymphedema in combination of debulking and physiologic procedures: a case report

Gathariki Mukami<sup>1</sup> , Khainga Stanley<sup>1</sup> , Aluora Kenneth<sup>1</sup> , Malungo Nang'andu<sup>1</sup> , Ocholla Laura<sup>2</sup> , Amuti Thomas<sup>3</sup> 

<sup>1</sup>Thematic Unit of Plastic Surgery, Department of Surgery, University of Nairobi, Nairobi, Kenya

<sup>2</sup>University of Nairobi, College of Health Sciences

<sup>3</sup>Department of Human Anatomy, University of Nairobi

**Correspondence to:** Mukami Gathariki; email: mukamigathariki.mg@gmail.com

Received: 19 Jun 2021; Revised: 27 Feb 2022; Accepted: 10 Mar 2022; Available online: 14 Apr 2022

## Summary

Lymphedema has a high incidence and various causes including filariasis in developing countries and as complications following oncological surgery in developed countries. It reduces patients' quality of life, productivity and currently lacks a cure. Current management involves debulking or physiological methods, with debridement being the preferred debulking method and lymph node transfer, the preferred physiological option. Most reports on the management of lymphedema or its associated outcomes have reported the use of either of these modalities with favourable outcomes, albeit some complications. There is however paucity of documented cases where a patient underwent both debulking and physiological treatment in management of chronic lymphedema and our case study reports on the same, with favourable outcome and minimal complications.

Our patient, a 30 year old female presented with an 8 year history of slowly progressive right lower limb

oedema. Physical examination revealed marked right lower limb swelling that was non-pitting, non-tender, erythematous, with marked thickening of skin, yellowing of the nails and a positive stemmer sign. Lymphoscintigraphy revealed hypoplastic lymphatic channels and faulty valves. Debulking using modified Charles procedure and vascularised lymph node transfer were done within a one month interval. Ten months later, she is doing well with no relapse.

**Keywords:** Lymphedema, Charles' procedure, Lymph node transfer.

Ann Afr Surg. 2022; 19(4): 221-225

**DOI:** <http://dx.doi.org/10.4314/aas.v19i4.11>

**Funding:** None

© 2022 Author. This work is licensed under the Creative Commons Attribution 4.0 International License.

## Introduction

Lymphedema is a chronic progressive disorder, defined as an abnormal limb swelling caused by accumulation of increased amounts of high protein interstitial fluid (ISF) secondary to defective lymphatic drainage in the presence of near normal net capillary filtration (1). In developing countries, the common causes are

podoconiosis and filariasis (2). In developed countries, lymphedema tends to occur secondary to oncologic surgery when draining lymph nodes have to be removed or irradiated to avoid tumour spread. Other identified causes include: burns, trauma, and infection.

Lymphedema is categorized into primary and secondary. Primary lymphedema is caused by a dysfunction in the lymphatic system while secondary, results from insults following surgery, trauma or infection. (3). Chronic deposition of protein rich lymphatic fluid in the interstitial space stimulates inflammation, leading to fibrosis and further damage to the lymphatics with resultant cycle of deterioration (4,5,6). This results in a grossly enlarged extremity with increased susceptibility to infection, functional impairment and psychosocial morbidity (7,8,9)

Various treatment include non-surgical options like: compression garments, manual lymphatic drainage, exercise and skin care. Previously, either debulking or physiologic management has also been employed. Debulking involves excision of the excess skin and subcutaneous tissue down to the deep fascia with skin grafting of the defect or liposuction of the excess subcutaneous tissue with resultant immediate improvement in function. Physiologic procedures promote clearance of lymphatic fluid from the interstitial space and include lymphovenous anastomosis (LVA) and vascularized lymph node (VLN) transfer. However, since they do not directly eliminate the solid component, any surgical plan without an excisional component falls short of fully addressing the issue at hand. This is particularly true for the more advanced stages as seen in this case. Therefore, understanding the efficient and timely management of lymphedema is paramount.

### Case presentation

A 30 year old female teacher was referred to our centre in May 2019, with a long standing history of primary lymphedema affecting her right lower limb, since 2011, was gradual on onset and worsened over several months. It was non pitting, and associated with severe pain. The pain and associated skin changes were debilitating to the extent that she could not stand for long periods as her profession requires her to. She reported of no comorbidities or family history of the same. Prolonged history of travel as well as stigmata for infections (filariasis) and malignancy were also ruled out. She also

did not have any previous surgeries done on the leg or any history of trauma.

Physical examination revealed marked swelling of the right lower limb with non-tender, non-pitting oedema with erythema and marked thickening of the skin. elephantiasis nostra verrucosa, which is an area of cobble-stoned, hyperkeratotic, papillomatous plaques most commonly seen on the shins. The patient was also noted to have yellowing of the nails. Patient was also noted to have a positive Stemmer sign, which is inability to pinch the dorsal aspect of skin between the first and second toes. Based on these findings, the lymphedema was at stage four.

Routine examination did not reveal any significant findings and despite being compliant, conservative management had failed to reduce the limb significantly.

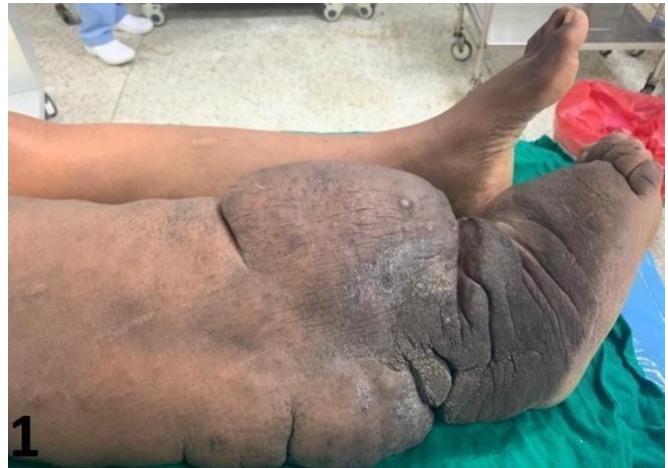

Figure 1: Figure showing the swollen affected limb pre-operatively.

As part of her assessment, a lymphoscintigraphy was done which showed that she had hypoplastic lymphatic channels and faulty valves. The first procedure done was surgical debulking using the modified Charles procedure below the knee to excise the excess skin and subcutaneous tissue with a split thickness skin grafting with the thigh as a donor site. The patient was taken to the ward following this initial procedure, put on analgesics and antibiotics for a period of five days. The recipient site was opened on the fifth day while the donor site was exposed on the seventh day. Serial wound care was then offered after this and the patient was retained in the ward for this period of time.

A month later, a vascularized lymph node transfer, where the submandibular lymph nodes were the donor lymph nodes, were anastomosed to the inguinal lymph nodes. Following the procedure, she was transferred to the ward for recovery.

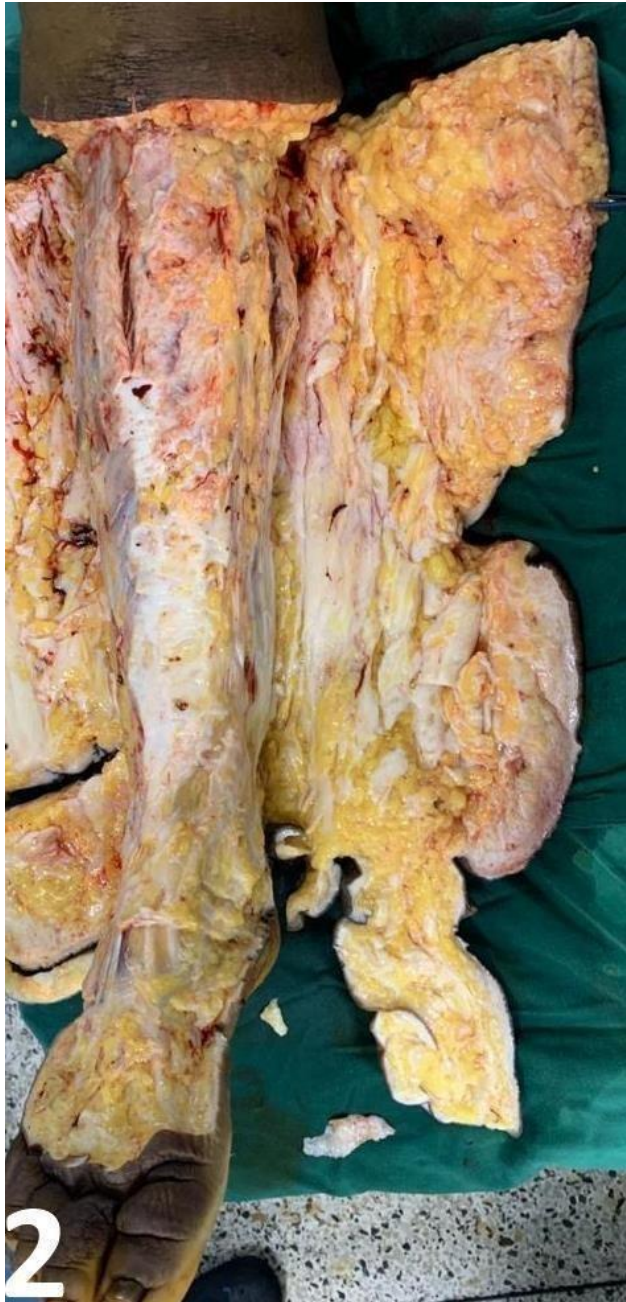


Figure 2. Figure showing the swollen affected limb pre-operatively.

Other than pain, she did not report any other complications. For the pain, tramadol was administered for the initial 2 days following which she was placed on

paracetamol for the remaining 12 days she was in the wards. She was able to ambulate after 7 days post-op and was discharged after 14 days.

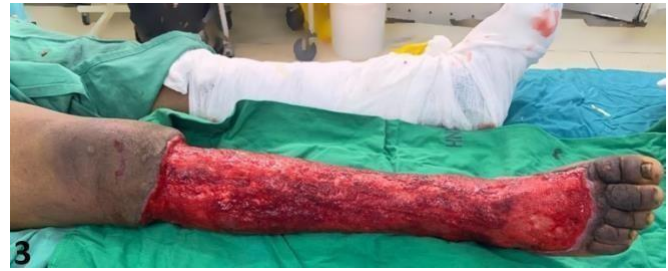

Figure 3. Figure showing the limb, post-operatively prior to skin grafting.

Check-up was done regularly for 10 months via teleconferencing as she lives remotely and was not been able to travel due to the COVID situation in the country. Within the 10 months, she did not complain of symptoms suggestive of disease recurrence and she reported that the results were aesthetically satisfactory. Through the calls, she also noted that she has since been able to resume her normal duties as a teacher.

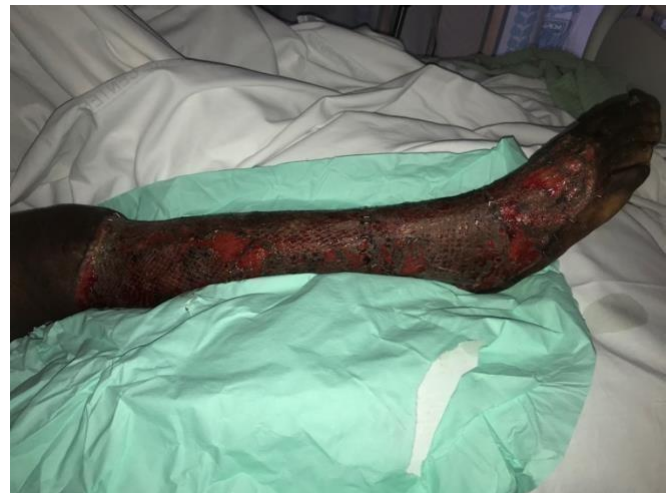

Figure 4. Figure showing the limb post-skin grafting

### Discussion

Lymphedema is defined as edema present for more than 3 months. It is usually underrecognized and undertreated. It is also associated with a lot of social stigma and reduction in the quality of life (2). The goals of lymphedema therapy are to restore function, reduce physiologic and physical suffering and prevent the development of infection. There are various modalities that can be employed in the management of



lymphedema. These include surgical and physiologic modalities. (12)

Debulking, over the years has been thought to be only palliative and not curative according to the guidelines of the International Society of Lymphology (2). It has therefore been reserved only for patients who do not improve with conservative management or for cases in which the extremity is so large that it impairs daily activities and prevents successful conservative management (2). It can be divided into 3 broad approaches: resective interventions, liposuction, and microsurgical procedures. Resective approaches involve radical excision of skin and subcutaneous tissue with delayed skin grafting (13). All resection procedures have been reported to result in significant morbidity and have had high complication rates (13). Suction-assisted lipectomy offers a much less invasive alternative to surgical resection, with greatly reduced morbidity and similar outcomes. It however is associated with microvascular injury to underlying vessels especially if not done with caution. Research has shown that surgical management has its limitations, with poor wound healing, sensorineural damage, hypertrophic scarring, graft necrosis, exophytic keratosis, and recurrence of lymphedema being reported (11). Several case reports and studies done on the same have revealed favourable outcomes following debridement such as Iwao et al (2004) (14) and Pitcher et al (2015) (13), in treatment of elephantiasis nostras verrucosa and Grada et al (2017) (11) despite some cases of the aforementioned limitations.

Physiologic procedures, on the other hand aim to improve lymphatic drainage. Multiple techniques have been described including omental transposition, lymphovenous anastomosis (LVA) and vascularized lymph node (VLN) transfer (11). Lymph nodes are not only immunologic stations but also perform fluid reabsorption through lymph filtration. Thus, lymph nodes also play a fundamental role in the pathophysiologic process of lymphedema because of their fluid reabsorption capacity, a feature that is often ignored. With their removal, replacement may be considered to augment lymphatic drainage of the affected area. The exact mechanism by which VLNT

improves lymphedema is still debated, but two leading theories have been described. The first is that transferred lymph nodes act as a sponge that absorbs local lymphatic fluid and redirects it into the vascular system. The second theory is that transferred lymph nodes produce vascular endothelial growth factor-C (VEGF-C) which induces local lymphangiogenesis by formation of spontaneous efferent and afferent connections between the transferred nodes and the recipient site (10). Examples of dreaded complication of VLNT is the development of secondary lymphatic dysfunction at the donor site. Similar to the surgical debridement, several case studies have reported several favourable outcomes with lymph node transfer, such as Ketan et al (2015) (16) and Ghazi et al (2013) (17) in treatment of limb lymphedema. A literature review by Ashvin et al (2015) (18) also reported similar findings however noted that because of methodological shortcomings comparative studies with uniform patient selection and monitoring are lacking.

Excisional techniques, aim to remove the affected tissues thus reducing the lymphedema related load. These methods include, Suction assisted removal of subcutaneous tissue which proves to be quite difficult due to the extensive subcutaneous fibrosis that is present. The Charles procedure can be used. It involves radical excision of skin and subcutaneous tissue followed by skin grafting using the skin that was excised. Van der Walt et al developed a modified Charles Procedure in which negative pressure dressing is employed following debulking surgery with skin grafting delayed for 5-7 days. (19).

In the case presentation above, we decided to employ both physiologic and debulking techniques so as to improve the overall outcome. Most case reports highlight the use of one technique either physiologic or debulking however good outcomes have been noted with combination techniques. In China, for example, Chen et al (2020) (20), were able to achieve good functional outcomes with combined lymph node transfer and modified Charles' procedure. The final outcome, similar to ours, was quite satisfactory. In our case, pain was the only complication and the patient was pleased with the final result, was able to return to her teaching

job and stand for long hours without fatigue as experienced before.

### Conclusion

Lymphoedema is usually under recognized and under treated. Some goals of therapy include restoration of function, prevention of infection and alleviation of physical and psychological suffering. Treatment modalities can be physiological or debulking. In this case, both options were used with resultant improvement in the patient's outcome.

### Conflict of interest

None to disclose

### Author contributions

GM lead in writing the original draft. All other tasks were shared equally.

### References

1. Rockson SG and Rivera KK. Estimating the population burden of lymphedema. *Ann N Y Acad Sci.* 2008;1131(1):147–154.
2. Hadamitzky C, Pabst R, Gordon K, et al. Surgical procedures in lymphedema management. *Journal of Vascular Surgery: Venous and Lymphatic Disorders.* 2014; 2(4), 461–468.
3. Allen RJ and Cheng MH. Lymphedema surgery: patient selection and an overview of surgical techniques. *J Surg Oncol.* 2016;113(8):923–931.
4. Avraham T, Yan A, Zampell JC, et al. Radiation therapy causes loss of dermal lymphatic vessels and interferes with lymphatic function by TGF-beta1-mediated tissue fibrosis. *Am J Physiol Cell Physiol.* 2010; 299:589–605.
5. Zampell JC, Yan A, Elhadad S, et al. CD4(b) cells regulate fibrosis and lymphangiogenesis in response to lymphatic fluid stasis. *PLoS ONE.* 2012; 7(11):e49940.
6. Cuzzzone DA, Weitman ES, Albano NJ et al. IL-6 regulates adipose deposition and homeostasis in lymphedema. *Am J Physiol Heart Circ Physiol.* 2014; 306:1426–1434.
7. Tobin MB, Lacey HJ, Meyer L, et al. The psychological morbidity of breast cancer-related arm swelling. *Cancer.* 1993; 72(11):3248–3252.
8. De Godoy JMP, Braile DM, de Fatima GM, et al. Quality of life and peripheral lymphedema. *Lymphology.* 2002; 35:72–75.
9. McWayne J and Heiney SP. Psychologic and social sequelae of secondary lymphedema: a review. *Cancer.* 2005; 104(3):457–466.
10. Aurora M, Kareh MD, Kyle Xu, et al. Surgical Management of Lymphedema. *Mo Med.* 2020; 117(2): 143–148.
11. Grada A and Phillips T. Lymphedema. *Journal of the American Academy of Dermatology.* 2017; 77(6), 995–1006.
12. Salgado CJ, Sassu P, Gharb BB, et al. Radical reduction of upper extremity lymphedema with preservation of perforators. *Ann Plast Surg.* 2009; 63(3):302-6.
13. Pitcher A, Pagan C, Kelvin S, et al. Excision of Elephantiasis Nostras Verrucosa Lesions in a Patient With Hereditary Lymphedema: Case Report and Review of the Literature. *The Journal of Foot and Ankle Surgery.* 2015; 54(4), 747–750.
14. Fumiya I, Kazuko C, Sato-Matsumura, et al. Elephantiasis Nostras Verrucosa Successfully Treated by Surgical Debridement. 2014; 30(6), 939–941.
15. Narushima M, Mihara M, Yamamoto Y, et al. The intravascular stenting method for treatment of extremity lymphedema with multiconfiguration lymphaticovenous anastomoses. *Plast Reconstr Surg.* 2010; 125(3):935-43.
16. Patel KM, Lin CY, Cheng MH, et al. A Prospective Evaluation of Lymphedema-Specific Quality-of-Life Outcomes Following Vascularized Lymph Node Transfer. *Ann Surg Oncol.* 2015; 22, 2424–2430.
17. Althubaiti GA, Crosby MA, Chang W, et al. Vascularized Supraclavicular Lymph Node Transfer for Lower Extremity Lymphedema Treatment. *Plastic and Reconstructive Surgery.* 2013; 131(1):133e-135e.
18. Raju A and Chang DW. Vascularized Lymph Node Transfer for Treatment of Lymphedema. *A Comprehensive Literature Review. Annals of Surgery.* 2015; 261(5): 1013-1023.
19. Van der Walt JC, Perks TJ, Zeeman BJ, et al. Modified Charles procedure using negative pressure dressings for primary lymphedema: a functional assessment. *Ann Plast Surg.* 2009; 62(6): 669-75.
20. Chen SH, Cem Yildirim ME, Mousavi SA, Chen HC. Long-term functional outcomes upon application of split-thickness skin graft around major joints in HCC (Hung-Chi Chen)-modified Charles' procedure for advanced lymphedema. *Asian J Surg.* 2021; 44(1):169-173.