

Empyema Thoracis- The Role of Open Thoracotomy with Decortication in the Era of Video-assisted Thoracoscopic Surgery

Vikram Sindgikar , Tejaswini Vallabha , Mallikarjun Patil , Girish Kullolli , Samhitha Reddy 

Department of General Surgery, BLDEDU's Shri B M Patil Medical College Hospital, Vijayapur, Karnataka, India

Correspondence to: Vikram Sindgikar; email: vikram.sindgikar@bldedu.ac.in

Received: 30 Sep 2021; Revised: 23 Jun 2022; Accepted: 27 Jun 2022; Available online: 26 Aug 2022

Abstract

Background: Empyema Thoracis, a condition in which purulent fluid accumulates within the pleural cavity, is commonly caused by bacterial infection (both Gram-positive and Gram-negative), such as *Mycobacterium tuberculosis*, and rarely by fungal infection. Timely intervention significantly reduces morbidity and mortality. Surgical intervention is needed in advanced disease. This study aimed evaluate decortications performed through video-assisted thoracoscopic surgery (VATS) and open thoracotomy. **Methods:** This retrospective study included 47 patients who underwent decortications by either VATS or open thoracotomy for empyema Thoracis at the Department of Surgery of, BLDE DU Shri B M Patil Medical College from May 2015 to August 2020. **Results:** Tuberculosis was the most common etiologic factor for empyema Thoracis. In 19 patients who underwent VATS decortications, VATS was converted to open thoracotomy in 11 patients. Only 8 patients achieved successful decortication with VATS. Thirty- nine patients (including 11 whose VATS was converted

to open thoracotomy) underwent successful open thoracotomy decortications. Thirty-two patients had postoperative bronchopleural fistula, and all cases were successfully managed conservatively. The timing of the surgical intervention is critical in reducing morbidity and mortality. The more advanced the disease, the higher the failure rate of VATS in attaining complete decortications. **Conclusion:** Open thoracotomy decortication remains the gold standard in attaining complete decortications in advanced empyema Thoracis.

Keywords: Empyema Thoracis, Tuberculosis, Open thoracotomy, Video-assisted thoracoscopic surgery, Decortication

Ann Afr Surg. 2022; 19(4): 175-179

DOI: <http://dx.doi.org/10.4314/aas.v19i4.3>

Funding: None

© 2022 Author. This work is licensed under the Creative Commons Attribution 4.0 International License.

Introduction

Empyema thoracis is the collection of purulent fluid within the pleural space (i.e., between the parietal pleura and the visceral pleura). It is one of the complications of pneumonia usually caused by bacterial infections. In western countries, Gram-positive bacteria predominate, whereas in India (1), especially in the northern part of

Karnataka, tuberculosis continues to be the common cause of empyema in adults. In children, Gram-positive bacterial infections are common. Patients usually presents with lower respiratory tract symptoms such as fever, productive cough, and breathlessness. Initially, the disease starts as an exudative effusion, progressing

into multi-loculation, later forming a thick layer of inflammatory exudate coating the viscera, leading to fibrosis and lung collapse. Thus, the formation of thick corticate makes the disease less amenable to medical management and signifies advanced disease, requiring surgical intervention. Morbidity significantly increases as the disease progresses from effusion to lung collapse. Thus, early intervention reduces the morbidity and mortality of the patient as well as financial burden the disease entails. Modalities of treatment ranges from needle aspiration, intercostal tube drainage, and surgical intervention such as video-assisted thoracoscopic surgery (VATS) or open thoracotomy decortication. Globally, surgical intervention is shifting from open surgical procedures to minimally invasive procedures, with definite advantages. However, whether open thoracotomy with decortication is becoming obsolete is unknown. Furthermore, is the era of open surgical procedures ending? This study aimed to compare the two surgical procedures, open thoracotomy with decortications and VATS decortications, in the treatment of empyema thoracis.

Materials and Methods

This retrospective study was conducted at the Department of Surgery of BLDE DU Shri B M Patil Medical College from May 2015 to August 2020. Institutional ethical approval was obtained (BLDE(DU)/IEC/481/2020-21). Patients diagnosed with empyema Thoracis who underwent thoracotomy decortication by VATS or open procedure and by VATS converted to open thoracotomy were included. Patients diagnosed with empyema Thoracis who were treated with non-surgical modalities were excluded from the study. Patients with a disease duration ≤ 3 weeks underwent VATS decortications, where as those with a disease duration >6 weeks underwent thoracotomy decortication. The type of surgery for those with a disease duration between 3 and 6 weeks were left to the discretion of the surgical team. The same surgical team performed the surgeries. The patients' characteristics were noted, including age, sex, duration of symptoms, etiology of the disease, associated complications such as bronchopleural fistula, time from the onset of the disease

to surgical intervention, type of procedure, cause for conversion from VATS to thoracotomy(if any), attainment of complete decortication, lung compliance post-procedure, morbidity with respect to post-operative complications, persistence of air leak, duration of hospital stay after surgery, and mortality.

Results

A total of 47 patients who satisfied the inclusion criteria were included in the study. Of 47 patients, 7 (14.9%) were 0–30 years old, 35 (74.5%) were 31–50 years old, 5 (10.6%) were 51–70 years old; the youngest patient was 6years old (Table 1). Of 47 patients, 42 (89%) were males and 5 (11%) were females.

Table 1. Age distribution.

Age (years)	No. of patients
0–10	2
11–20	2
21–30	3
31–40	13
41–50	22
51–60	4
61–70	1

The most common cause of empyema thoracis in this study was tuberculosis (82.9%) (Table 2). Tuberculosis was diagnosed based on signs of tuberculosis in chest radiography and result of sputum acid-fast bacteria test. All patients positive for tuberculosis were started on anti-tubercular therapy.

Table 2. Disease etiology.

Etiology	No. of patients
Tuberculosis	39
Gram-positive bacterial infection	6
Fungal infection (mucormycosis)	1
Mesothelioma	1

Most of the patients presented with more than 6 weeks of disease duration before surgery (57.4%) (Fig. 1). Patients with disease durations of 3, 3–6, and >6 weeks were categorized as being in the exudative, fibrin purulent, and fibrinous stages of empyema Thoracis, respectively. In this study, 16 patients had a disease duration of 3–6 weeks, and they were initially managed

using an intercostal drainage tube and anti-tubercular therapy. Later, 15 of these patients underwent VATS decortications, and 1 patient with relatively advanced disease underwent open thoracotomy decortication. Four patients with a disease duration <3 weeks and with loculated fluid collection underwent VATS decortication. Meanwhile, 28 patients with a disease duration >6 weeks underwent open thoracotomy decortication.

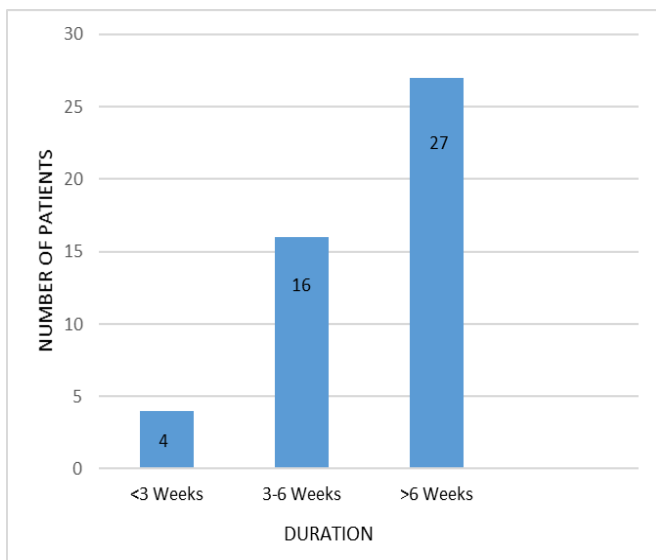


Figure 1. Duration of disease according to the timing of surgical intervention

Of 47 patients, 28 (59.5%) patients underwent open thoracotomy decortication (Table 3). A total of 19 patients underwent VATS, which was converted to open procedure in 11 patients, and the remaining 8 patients had successful VATS decortication. A conversion rate of 57.89% was observed in this study. Eleven patients underwent successful open thoracotomy decortication converted from VATS.

Table 3. Type of procedure

Procedure (complete decortication achieved)	No. of patients
VATS decortication	8
Thoracotomy Decortication	28
Video-assisted thoracoscopic surgery converted to Open Thoracotomy Decortication	11

In all 47 patients, complete decortication was achieved either by VATS or open thoracotomy procedures. The success rate in attaining complete decortications was 42.10% for VATS and 100% for open thoracotomy. Complete lung expansion post-procedure was observed in 31 (66%) patients. Complete lung expansion, determined through the observation of the expansion of the decorticated lung reaching the rib cage on ventilation by the anesthetist on table. The remaining 16 (34%) patients had poor lung compliance secondary to fibrosis, which was probably due to advanced disease.

Under water seal drainage was placed in all the patients. The drain was removed once the air leak had stopped and/or drainage is <50mL. In 12 patients, the drain was removed on the second post-operative day. The drain was removed in <5 days in 17 patients, whereas 9 patients needed the drain for an average of 10 days; meanwhile, 6 patients needed the drain for >2 weeks. Three patients died.

Table 4. Post-operative bronchopleural fistula

Post-operative air leak (bronchopleural fistula)	Video-assisted thoracoscopic surgery (no. of patients)	Open Decortication (no. of patients)	Total
Less than 5 days post op	7	10	17
5 to 10 days	1	8	9
More than 10 days	-	6	6

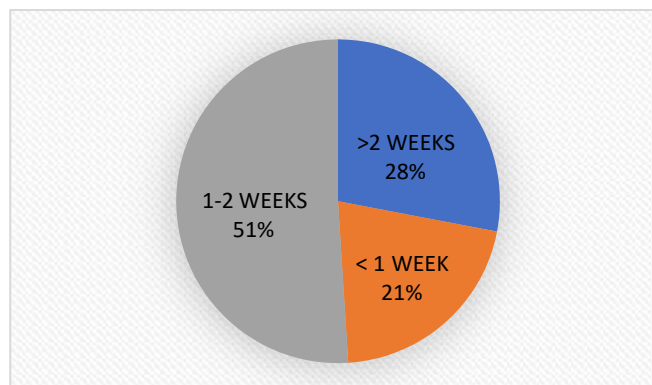


Figure 2. Duration of hospital stay (from the time of surgery)

Post-operative air leak (bronchopleural fistula) was observed in patients (Table 4). Of 47 patients, 32 had post-operative bronchopleural fistula, which was

managed successfully by non-operative management. Most (34, 72.3%) of the patients had <2 weeks of hospital stay post-surgery. Among them, 10 patients stayed for <1 week, whereas 24 patients (including the 3 patients who died) stayed for 2 weeks. Only 13 (27.6%) patients had a hospital stay >2 weeks post-surgery (Fig. 2). Three patients died secondary to respiratory failure after the procedure.

Discussion

Most western literature suggests that the causative organisms of empyema Thoracis are usually Gram-positive bacteria. However, recent literature suggests that anaerobes and staphylococcal species have replaced *S. pneumoniae* as the major pathogen in surgically treated empyema. Also, anaerobic isolates were found in higher incidence in Community Acquired Pneumonia (CAP) than previously reported (2). In India, tuberculosis is the common cause of empyema in adults (3). In our study, we have observed that the most common cause was tuberculosis, accounting for 82.9%, whereas Gram-positive bacterial infection was observed in 12.76%. In the study conducted by Ozol et al., *Staphylococcus aureus* was the most frequent bacteriological agent followed by *Streptococcus pneumoniae* and anaerobes (4). Most of the patients in our study were male (89%). In a study conducted by Rajgopal and Shah, 77.5% of the disease occurred in males and 22.5% occurred in females (5), but the disease does not have a sex predilection. The 41- to 50-year age group had the highest percentage (46.80%) of patients, followed by 31- to 40-year age group (27.65%).

The American Thoracic Society described three stages in the natural course of empyema Thoracis: exudative, fibrinopurulent, and organizing phases (6). The management significantly varies with each phase, from conservative management with antibiotics in the early exudative phase to surgical intervention in the later stages. Most of the cases are managed by thoracentesis or tube thoracotomy in the fibrinopurulent phase. As the disease progresses, surgical interventions such as decortication by either VATS or open thoracotomy are required, usually in the late fibrinopurulent and organized phases (7). Patients usually presents with

symptoms of fever, cough with expectoration, chest pain, and breathlessness (8).

In our study, 19 patients underwent VATS decortications, of whom 8 underwent successful decortications, with a success rate of 42.10%. Success of decortication was assessed based on complete removal of the corticate (covering the lung surface) from all the lobes of the lung and from the interlobar fissure. A prospective study by Waller and Rengarajan found VATS to be successful in 58% of cases compared with open surgery in patients with chronic empyema (9). A study conducted by Chambers et al. indicated that eight studies that compared VATS in early and late empyema reported conversion rates to open decortication of 0–3.5% in the early stage and 7.1–46% in the late stage (10). In our study, VATS was converted to open procedure in 11 patients, with a conversion rate of 57.89%. In most cases, the reason for conversion was thick corticate and dense adhesions (late fibrinopurulent and chronic stages) that could not be adequately debrided by VATS. In some patients, poor visualization by bloody field during dissection was the reason for conversion. Those who underwent successful decortications by VATS had less dense adhesions and were in the early phase of empyema, i.e., exudative and early fibrinopurulent stages. A total of 28 patients underwent open thoracotomy decortications because of advanced disease, late presentation, and thick corticate. All patients underwent successful decortication (100%). Eleven patients whose procedure was converted from VATS also underwent successful open thoracotomy decortications. In our study, despite complete decortication, 16 patients had incomplete lung expansion post-procedure, mainly because of underlying lung fibrosis. All these patients had tuberculosis as the cause of empyema. Post-operative air leak was the common complication observed. A total of 32 patients had air leak, and all cases were managed conservatively. Air leak subsided early in those who underwent VATS (87.5% vs. 25.6%) at day 5 and 12.5% vs. 20.51% at day 10. Cardillo et al. reported that VATS had significantly better results than open decortication in terms of operative time ($p= 0.0001$), pain ($p= 0.0001$), post-operative airleak ($p= 0.004$), hospital stay ($p= 0.020$),

and time to return to work ($p=0.0001$) (11). In our study, there were three mortalities, accounting for 6.38%, and the cause was respiratory failure. In-hospital mortality in the adult population is approximately 16.1%. (12).

The meta-analysis conducted by Massoud Sokouti et al comparing the two above procedures for empyema thoracis concluded that the worldwide, the beneficial effects of VATS have been widely reported in treatment of early stages of empyema (i.e., stage II, with limited successful performance at stage III). The results of the current systematic review and meta-analysis suggest no major trends of superior outcomes with VATS versus open surgery decortication in the treatment of empyema thoracis (13).

Conclusion

Empyema thoracis can affect patients of all age groups, with peak incidence in the fourth decade. Tuberculosis is the common etiological factor in our region. Earlier intervention can improve the result and lower morbidity. In advanced stages, open thoracotomy decortications have a higher success rate in attaining complete decortications than VATS.

VATS decortication had fewer post-operative complications, but it has significant conversion to open procedure with advanced disease. Thus, open thoracotomy decortication remains the gold standard in attaining complete decortications in advanced empyema thoracis.

Conflict of interest

None to disclose

Author contributions

All authors contributed equally to writing and editing the original draft.

References

1. Kundu S, Mitra S, Mukherjee S, et al. Adult thoracic empyema: a comparative analysis of tuberculous and nontuberculous etiology in 75 patients. *Lung India*. 2010; 4: 196-201.
2. Pinnola A, Kuo YH, Sciarretta JD, McIntyre A, Messier R, Davis JM. Bacteriology and Comorbidities in Patients Requiring Surgical Management of Empyema. *Am Surg*. 2018 Apr 01;84(4):599-603.
3. Malhotra P, Aggarwal AN, Aggarwal R, et al. Clinical characteristics and outcome of empyema thoracis in 117 patients. A comparative analysis of tubercular vs. non tuberculous aetiologies. *Respir Med*.2007; 101:423-30.
4. Ozol D, Oktem S, Erdinc E. Complicated parapneumonic effusion and empyema thoracis: microbiologic and therapeutic aspects. *Respir Med*.2006; 100:286-91.
5. Rajgopal AP, Shah KV. Empyema thoracis: a clinical study. *Ann Thorac Med*. 2007; 2: 14-7.
6. McCauley L, Dean N. Pneumonia and empyema: causal, casual or unknown. *J Thorac Dis*. 2015 Jun;7(6):992-8.
7. Redden MD, Chin TY, van Driel ML. Surgical versus non-surgical management for pleural empyema. *Cochrane Database Syst Rev*. 2017 Mar 17;3:CD010651.
8. "Empyema: MedlinePlus Medical Encyclopedia". *medlineplus.gov*. Retrieved 2021-06-19.
9. Waller DA, Rengarajan A. Thoracoscopic decortication: a role for video assisted surgery in chronic postpneumonic pleural empyema. *Ann Thorac Surg*.2001;71:1813-6.
10. Chambers A, Routledge T, Dunning J, et al. Is video-assisted thoracoscopic surgical decortication superior to open surgery in the management of adults with primary empyema? *Interact Cardiovasc Thorac Surg*.2010;11: 171-7.
11. Cardillo G, Carleo F, Carbone L, et al. Chronic postpneumonic pleural empyema: comparative merits of thoracoscopic versus open decortication. *Eur J Cardiothorac Surg*. 2009; 36:914-8.
12. Grijalva CG, Zhu Y, Nuorti JP, Griffin MR. Emergence of parapneumonic empyema in the USA. *Thorax*. 2011 Aug;66(8):663-8
13. Massoud S, Ramin S, Saeid P, et al. Treating empyema thoracis using video-assisted thoracoscopic surgery and open decortication procedures: a systematic review and meta-analysis by meta-mums tool. *Arch Med Sci* 2019;15(4):912–935