

# Pulmonary Hydatidosis in Children: A Different Pattern from Adults?

Nesrine Chebil , Sondes Sahli , Fatma Fitouri , Senda Houidi , Arij Zouaoui , Yasmine Houas , Yosra Kerkeni , and Riadh Jouini 

Department of Pediatric Surgery A, University of Tunis El Manar, Tunis, Tunisia

**Correspondence to:** Dr. Nesrine Chebil. Email: chebilnesrine@yahoo.fr

Received: 01 April 2021; Revised: 16 Oct 2021; Accepted: 20 Oct 2021; Available online: \*\*\*

## Abstract

**Background:** Hydatidosis is a major health problem in many countries. It is a parasitic disease that can affect adults as well as children. Hydatid cyst often involves the lungs in children. Given the anatomical and physiological differences between children and adults, generalization from adult studies is inappropriate. **Methods:** To determine particularities of lung echinococcosis in children, we conducted a retrospective study of all cases treated for hydatid cyst of the lung at our department. **Results:** One hundred fifteen children (average age, 7 years 6 months; range, 3–15 years) were managed for pulmonary hydatid cyst, which corresponds to 66% of all hydatid localizations. Male predominance was noted (sex ratio=1.94). Cough (60.9%) and chest pain (59.1%) were the most common clinical features. Fever and fatigue were noted in 57 (49.5%) and 34 (29.5%) cases, respectively. Giant cysts

were seen in 11 patients (10%). The cysts were mostly diagnosed when they are intact (68.7%). Mixed hepatic and pulmonary cysts were noted in 27 cases (4.25%). Conservative muscle-sparing surgery was performed in all cases. Complications were noted in 20% of the cases. **Conclusion:** As hydatidosis has a different pattern in children, optimal management requires a better knowledge of its particularities in this age group.

**Keywords:** Hydatid cyst, Lung, Particularities, Children

**Conflict of interest:** None

**Funding:** None

© 2021 Author. This work is licensed under the Creative Commons Attribution 4.0 International License.

## Introduction

Hydatid disease is known as echinococcosis or hydatidosis, and the causative microorganism is usually a tapeworm parasite called *Echinococcus granulosus* (1). This zoonosis is endemic to many sheep- and cattle-rearing regions of the world, particularly in the Mediterranean countries, including Tunisia, where it continues to represent a major health problem (2). Humans are accidental hosts by eating tapeworm eggs (1). It commonly starts during childhood or adolescence (3). In children, the lung is the most common site of localization of the larval form, which is the cyst (4). This

can be explained by the higher patency of the hepatic filter (first filter) in children, thus permitting the parasite to reach the lungs (second filter) (5). There are certain unique characteristics of the pediatric hydatid cyst (6). We aimed to review the particularities of the clinical presentations, diagnosis, surgical treatment, and post-operative outcomes of pulmonary hydatid cysts in children.

## Materials and methods

This retrospective cross-sectional study was performed

of all cases diagnosed and treated for hydatid cyst of the lung at the Department of Pediatric Surgery of our institution. It was carried out from January 1, 2005, to December 31, 2018. Data recorded included patients' demographics, symptoms, imaging and laboratory findings, intraoperative data, complications, and recurrence. Ethical approval was obtained from the head of the Department of Pediatric Surgery and from the ethics committee of our institution (Approval ref. number 2021-16).

## Results

One hundred fifteen children were managed for pulmonary hydatid cyst, which corresponds to 66% of all hydatid localizations. A male predominance was noted (sex ratio=1.94). The average age was 7 years and 6 months and ranged from 3 to 15 years. The most affected age group was 7–10 years. In our study, 86.1% of the children resided in a rural area, and their families were involved in animal husbandry. Cough and chest pain were the chief complaints in 60.9% and 59.1% of the cases, respectively. The other clinical features were hemoptysis (20% of the cases), vomiting (17.4% of the cases), and dyspnea (19% of the cases). Fever and fatigue were noted in 57 (49.5%) and 34 (29.5%) of the cases, respectively. The hydatid cyst was fortuitously discovered on a chest X-ray in 5.2% of the cases. Physical examination was normal in 17.4%. Otherwise, it was non-specific. Pulmonary examination found ronchi in 7.8% of the patients and dullness at percussion in 11.3%. A homogeneous hepatomegaly reflecting a hydatid cyst of the liver was found in 7.8%. Plain chest roentgenogram was sufficient to confirm the diagnosis of pulmonary hydatidosis in 78.2% of the cases, whereas in other patients (21.8%), chest ultrasonography and computed tomography were needed. A unique cyst was noted in 86% of the cases. The lesions were unilateral in 92.2% of the cases and right-sided in 48.7% of the cases. Cysts were located preferentially in the lower lobes (56.5%), with no statistical significance (Table 1). Ten percent of the patients with giant cyst had a median age of 12 years (Figure 1) (Table 2). The cysts were complicated in 31.3% of the cases. Chest computed

tomography (Figure 2) and chest ultrasound were performed in 31 patients.

Table 1. Localization of cysts

Localization	Unilateral		Bilateral	Total
	Right	Left		
Cases	56	50	9	115
Pourcentage (%)	48.7	43.5	7.8	100

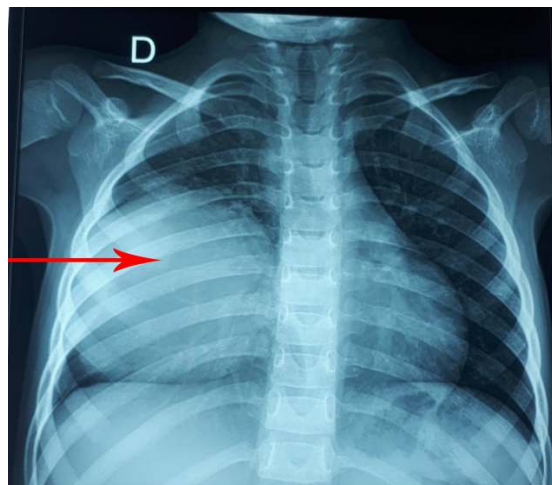


Figure 1. Pre-treatment chest radiogram showing a giant cyst of the right lung (arrow).

Table 2. Size of cysts

Size of cysts (millimeters)	Number of patients	Percentage (%)
<50	22	19
50-100	82	71
>100	11	10
Total	115	100

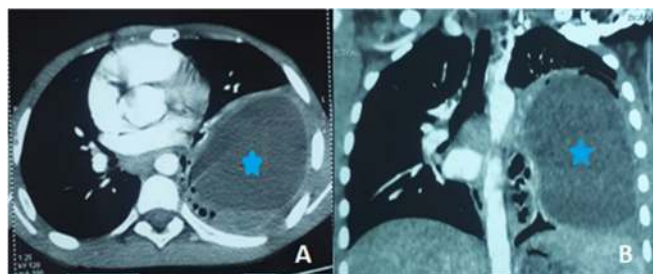


Figure 2. Thoracic computed tomography scan showing an intact hydatid cyst (marked with a star) of the left lung: axial (A) and coronal (B) sections.

Magnetic resonance imaging (MRI) was not performed. An intra-abdominal localization was detected with a systematic ultrasonography in 29 patients (27 of which were located in the liver), and 68.7% of the patients had an intact cyst. Routine laboratory tests found an elevated inflammatory marker in 53.9% of the cases and hypereosinophilia in 13% of the cases. Enzyme-linked immunosorbent assay (ELISA) was the only serological test available in our institution. It was positive in 7 (87.5%) of 8 patients. All our patients underwent posterolateral thoracotomy and conservative muscle-sparing surgery. An intact endocystectomy (Ugon's procedure) was performed in patients with small intact cysts (39.1%) (Figure 3).

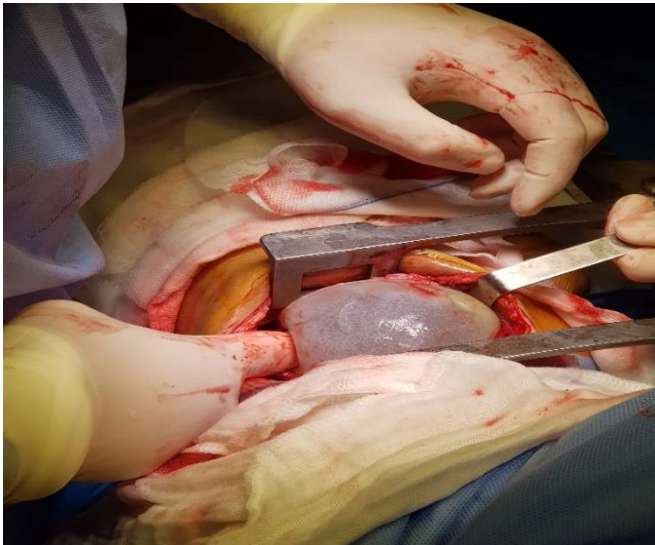


Figure 3. Intraoperative photograph showing removal of the cyst with its intact membrane (Ugon's procedure).

Cystostomy (Barrett's procedure) was preferred in patients with complicated cysts or cysts larger than 3 cm (60.9%). None of the patients in this study had a cystopericystectomy (Perez-Fontana's procedure). Medical treatment was prescribed in 7 cases. The indications for antiparasitic therapy were multiple pulmonary hydatid cysts in 1 patient, ruptured cysts in 4 patients, and multiple hydatid cysts of the liver in 2 patients. No major side effects were noted. Post-operative complications were observed in 23 patients (20%) (Table 3): prolonged air leaks in 18 patients, emphysema in 1 patient, atelectasis in 3 patients, and

chylothorax in 1 patient. They evolved favorably with chest physical therapy and analgesia. The patient who developed a chylothorax was managed conservatively with enteric rest and total parenteral nutrition, with good outcome. Recurrences were seen in 6 patients (5.2%). No deaths were noted.

Table 3. Post-operative complications

Complications	Number of patients	Treatment
Pneumothorax	18 (78.2%)	Chest physiotherapy Prolonged drainage
Emphysema	1 (4.4%)	-
Atelectasis	3 (13%)	Chest physiotherapy Drainage
Chylothorax	1(4.4%)	Nil-per- mouth Total parenteral nutrition

## Discussion

Hydatidosis is endemic in Tunisia. The annual surgical incidence of hydatid disease is 15/100,000 in the Tunisian population (7). Lungs are the second localization in adults (18–35%), but it is the most common localization in children (47–77%) (2, 8). Although many of the recorded cases of cystic hydatidosis are in adults, most human infections occur during childhood and adolescence (4). Mean age of diagnosis ranges from 7 to 10 years in the pediatric series (2). Nevertheless, some authors reported cases of pulmonary hydatidosis in younger children: an 8-month-old infant in the series of Topçu et al. (9) and an 18-month-old patient in the series of Hafsa et al. (5). In children, male predominance is noted, with a sex ratio ranging from 1.2 to 2 (2, 8). The reason is that boys are more prone to play outside with animals than girls (3). In our study, the sex ratio was 1.94. However, there was no obvious sex tendency in adults (10), albeit some authors reported a slight female predominance (11). Rural origin was noted in 78.2% to 83% depending on countries and studies (8, 12). Concerning clinical presentation, fever and fatigue are more frequent in children; in contrast, bilioptysis, which is the result of a bilio-bronchial fistula of hydatid origin, was only seen in adults (13). Even in the pediatric series, clinical features can vary depending on age. In fact, Marghli et

al. found that fever is more frequent in younger children, whereas respiratory symptoms are more common in older children (2). In this study, cough and chest pain were the chief complaints (60.9% and 59.1% of the cases, respectively). The frequency of concomitant hepatic and pulmonary cysts was lower in children than in adults (14.3% vs 85.7%) (10, 13). Mixed hepatic and pulmonary cyst was found in 23.4% of our patients. The most frequent location was the lower lobes in both adults and children because of the increased blood flow in caudal regions (14). It was the same in our series, where cysts were located in 56.5% of the cases in the lower lobes. In children, cysts are more often discovered when they are still intact (65–71%) than in adults (35–57%) (2). In our patients, 68.7% had an uncomplicated cyst. In our series, 92.2% of the patients had a unique hydatid cyst. Because of the structure of the lungs allowing compression, the relatively higher elasticity of the lung tissue and the underdeveloped immune system in children, hydatid cysts can reach large sizes (12). A giant cyst is defined as a cyst whose largest diameter measures more than 100 mm. It is considered a distinct clinical entity usually encountered in adolescents and in children older than 10 years (7). In our series, 10% of the patients with giant cyst had a mean age of 12 years. Serodiagnostic reactivity can also be affected by age. In fact, children between 3 and 15 years old may exhibit decreased antibody response when compared with older patients (15). Nevertheless, in this study, ELISA was performed in 8 patients and was positive in 7 children (87.5%). As for imaging, MRI without contrast material seems to be a great alternative in the pediatric population. In fact, this examination can provide supplementary diagnostic value by showing internal membranes without radiation (16). None of our patients had MRI because of its high cost and also because MRI is always performed under general anesthesia in our institution.

Surgery is the treatment of pulmonary hydatid cyst whether it is symptomatic or not (2). In children older than 8 years, a Robert Shaw 26-F endo-tracheal tube can be used if the cyst is left-sided. In adolescents, it is possible to use a Carlens-type double-lumen tube. However, in young children a typical cuffed

endotracheal tube is preferred (2). When dealing with pediatric pulmonary hydatidosis, parenchymal damages should be allowed to heal, given the high recovery potential of lung tissue at a young age. The risk of reinfection should be considered, especially in areas where hydatid disease is endemic (17). Some authors recommended lung resection if the damage is greater than 50% of the lobe volume by cyst or if multiple cysts are present in the same lobe (18). This dogma increases the resection rates very severely. In pediatric patients, the volumes of lung lobes are smaller. If a child has a giant hydatid cyst (i.e., a cyst exceeding 10 cm in diameter), it will invade more than half of any lobe. Onal and Demir (17) reported cases of conservative treatment, even in giant cysts, with good outcomes. All of our patients had a conservative treatment, even those with giant cysts (10%). As musculoskeletal deformities develop in a significant proportion of children following thoracotomy, muscle-sparing surgery is highly recommended to decrease the incidence of these deformities (19). Pulmonary hydatidosis appears to be a milder disease in children, with a lower complication rate and better overall outcome.

Suppuration and atelectasis were the most frequent complications in children, whereas insufficient pulmonary expansion and prolonged air leaks were the most commonly reported complications in adults (13). We believe that these can be explained by the larger resection of pulmonary parenchyma in adults. No significant difference in recurrence was found between adults and children (20).

### Conclusion

In children, hydatidosis most often involves the lungs, with male predominance. Clinical features may vary depending on age. Children are less prone to develop concomitant pulmonary and hepatic cysts. Cysts are bigger in size and often discovered while intact. Surgical outcome is generally good, with fewer post-operative complications. A better knowledge of particularities of pulmonary hydatidosis in children is crucial for optimal treatment. Surgery must be as conservative as possible, especially in endemic countries like ours, with muscle-sparing approach.



## References

1. Stone McGuire L, Nikas D. Vein of Galen Malformation. *N Engl J Med*. 2020 Oct 8;383(15):e90. PMID: 33027572.
2. Berenstein A, Lasjaunias P. Arteriovenous Fistulas of the Brain. In: Berenstein A, Lasjaunias P, editors. *Surgical Neuroangiography: 4 Endovascular Treatment of Cerebral Lesions*. Berlin, Heidelberg: Springer Berlin Heidelberg; 1992. p. 267-317.
3. du Toit J, Bam JA, Mngomezulu V. Endovascular treatment of vein of Galen aneurysmal malformation. *South African Journal of Radiology*; Vol 13, No 1(2009)
4. Ogbole G, Adeleye A, Olatunji R. et al Vein of galen aneurysmal malformation in children: Challenges of imaging in an African setting. *West African Journal of Radiology*. 2013;20(1):45-9.
5. Child growth standards. Geneva, Switz: World Health Organization; World Health Organization [website] Available from: [www.who.int/childgrowth/standards/hc\\_for\\_age/en](http://www.who.int/childgrowth/standards/hc_for_age/en). Accessed 2021 ,Jun 21.
6. Malarbi S, Gunn-Charlton JK, Burnett AC et al Outcome of vein of Galen malformation presenting in the neonatal period. *Arch Dis Child*. 2019 Nov;104(11):1064-1069. doi: 10.1136/archdischild-2018-316495. Epub 2019 May 23. PMID: 31122925.
7. Kim DJ, Suh DC, Kim BM, Kim DI. Adjuvant Coil Assisted Glue Embolization of Vein of Galen Aneurysmal Malformation in Pediatric Patients. *Neurointervention*. 2018 Mar;13(1):41-47. Epub 2018 Mar 2. PMID: 29535897; PMCID: PMC5847889.
8. Hansen D, Kan PT, Reddy GD et al, Pediatric knowledge update: Approach to the management of vein of Galen aneurysmal malformations in neonates. *Surg Neurol Int*. 2016;7(Suppl 12):S317-S21.
9. Gupta A, Varma D. Vein of galen malformations: Review. *Neurology India*. 2004;52(1):43-53.
10. Puvabanditsin S, Mehta R, Palomares K, et al. Vein of Galen malformation in a neonate: A case report and review of endovascular management. *World J Clin Pediatr*. 2017;6(1):103-109. Published 2017 Feb 8. Orbach APSDB. Vein Of Galen Aneurysmal Malformation. 2017. In: *Primer on Cerebrovascular Diseases* [Internet]. Elsevier. 2. [482 - 7].
11. Rodesch G, Hui F, Alvarez H, Tanaka A, Lasjaunias P. Prognosis of antenatally diagnosed vein of Galen aneurysmal malformations. *Child's Nervous System*. 1994;10(2):79-83.
12. Berenstein A, Paramasivam S, Sorscher M, Molofsky W, Meila D, Ghatan S. Vein of Galen Aneurysmal Malformation: Advances in Management and Endovascular treatment. *Neurosurgery*. 2019 Feb 1;84(2):469-478. Erratum in: *Neurosurgery*. 2018 Sep 1;83(3):593. PMID: 29860355.