









Microsurgical Penile Replantation: Case Report

Aluora Kenneth¹ , Khainga Stanley¹ , Nang'ole Ferdinand¹ , Ikol James² , Were Andrew¹ 
, Gathariki Mukami¹ , Ajujo Martin¹ , Malungo Nang'andu¹ 

¹Thematic Unit of Plastic Surgery, Department of Surgery, School of Medicine, University of Nairobi. P. O. Box 19679 – 00202 Nairobi, Kenya.

² Kenyatta National Hospital. P. O. Box 20723 – 00202 Nairobi, Kenya

Correspondence to: Dr. Aluora Kenneth; email: aluorakenneth@gmail.com

Received: 12 Jan 2021; Revised: 14 Nov 2021; Accepted: 26 Nov 2021; Available online: 29 Dec 2021

Summary

Penile replantation is uncommon, with most data being case reports or case series. In our setting, replantation is fairly new despite penile amputations being common as a result of marital disputes and assault. Replantation remains the most ideal option for managing these cases. We present a case of penile replantation in a 17-year-old male after traumatic amputation following an assault. Some of the challenges we encountered included loss of skin and the glans with formation of a hypospadias. Nevertheless, the outcome was satisfactory with return of sensation and erection.

Keywords: Penile amputation, Penile replantation, Microsurgery, Penile reconstruction, hypospadias

Ann Afr Surg. 2022; 19(2): 130-134

DOI: <http://dx.doi.org/10.4314/aas.v19i2.12>

Funding: None.

© 2022 Author. This work is licensed under the Creative Commons Attribution 4.0 International License.

Introduction

Amputation of the penis is traumatizing to the patient, spouse, and family. Most cases of penile amputations documented result from self-mutilation, also known as Klingsor syndrome (1). Other causes include assault commonly by spouse, accidental amputation, circumcision, and iatrogenic (2,3). Various challenges facing penile replantation in developing countries include loss of the amputated part, lack of awareness on amputated part preservation and transportation by the public, poor referral systems, lack of equipment such as operating microscopes, and lack of microsurgical experts among others (4). Despite microsurgical penile reimplantation being an uncommon procedure, it is currently the ideal treatment option for penile amputation because it provides better sensory and

erectile function than non-microsurgical techniques (2,4,5).

Case report

A 17-year-old male was referred to our facility after assault by people known to him with machetes in what was reported as a family feud. During the assault, he had his penis amputated by a machete and also sustained laceration to his left ear and the left half of the parietal scalp. The amputated part was stored directly in ice, and pressure was applied on the stump with a piece of cloth. He was rushed to the hospital, which was 2 hours away. At the hospital, the patient arrived with reduced level of consciousness. He was given tetanus toxoid, analgesics, and antibiotic. A unit of blood was transfused, and his scalp and ear lacerations were sutured. Hemostasis of

the stump was achieved by clamping the vessels using artery forceps (Figure 1). The stump was wrapped in moist gauze, stored in a plastic bag that was stored in a cooler box with ice packs (Figure 2). After the stabilization, he was referred to our facility, which was 2 hours 15 minutes away. He presented 8 hours after the assault to our facility. He had no pre-existing medical condition and was neither a smoker nor user of any health risk substance. The patient was stabilized and prepared for the emergency procedure. The parent was counselled on the replantation procedure, and they fully consented. The patient was then taken to the theater 2 hours after arrival and 10 hours post-amputation. Patient was placed under general anesthesia, and a suprapubic cystostomy was performed by the urology team (Figure 1). The stump was then exposed, revealing a clean cut at the proximal penile shaft (Figure 1).

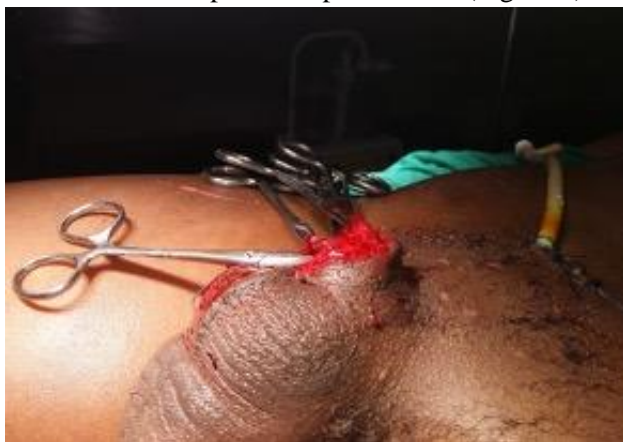


Figure 1. The stump.

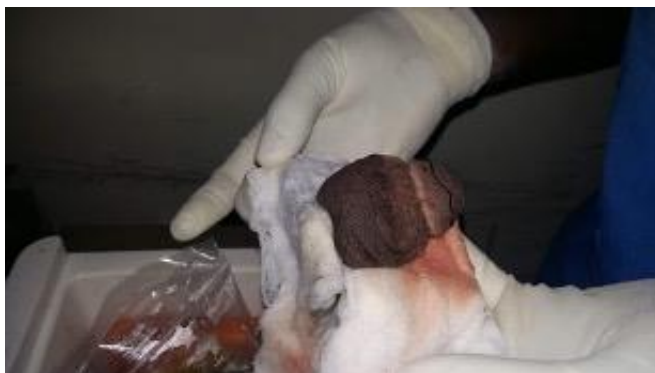

Figure 2. The amputated part.

The stump and amputated part were both prepared by cleaning them with saline using a syringe and gauze,

then the edges were freshened to remove any damaged tissue and debris. The structures identified were the urethra, corpora carvenosa and spongiosum, the superficial vein, and the deep dorsal vein, arteries, and nerves (Figure 3). The superficial vein was heavily crushed and could not be salvaged. The rest of the neurovascular bundles were freshened and prepared for anastomosis.

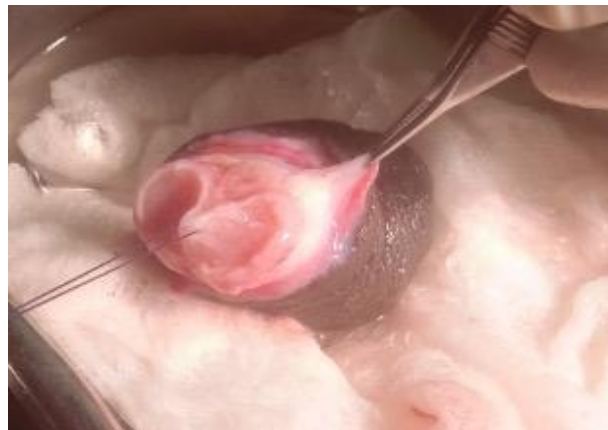


Figure 3. The amputated part post debridement.

Anastomosis of the penile urethra was performed using interrupted Vicryl 5.0 and a catheter passed through the urethra. Next, the tunica albuginea was approximated using Vicryl 3.0. The dorsal arteries then the dorsal veins were anastomosed, and finally, the dorsal nerves were co-opted all using nylon 9.0 interrupted sutures. Deep and superficial fascias were closed as a single layer with Vicryl 3.0. Glove drain was left in-situ, and the skin was closed (Figure 4). Light dressing was applied with gauze.

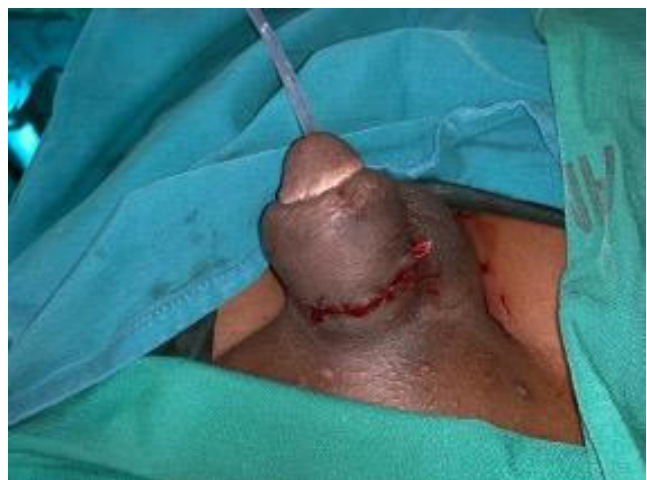

Figure 4. Penile gland immediately after replantation

Post-operatively, we transfused 3 units of blood and gave paracetamol, morphine, and tramadol for analgesia. We used enoxaparin (Clexane; Aventis Pharma Ltd., Midrand, Gauteng, South Africa) and aspirin for anticoagulation. Monitoring was done every 2 hours, and post-operative congestion was noted at 20 hours. The patient was taken back to theater for exploration.

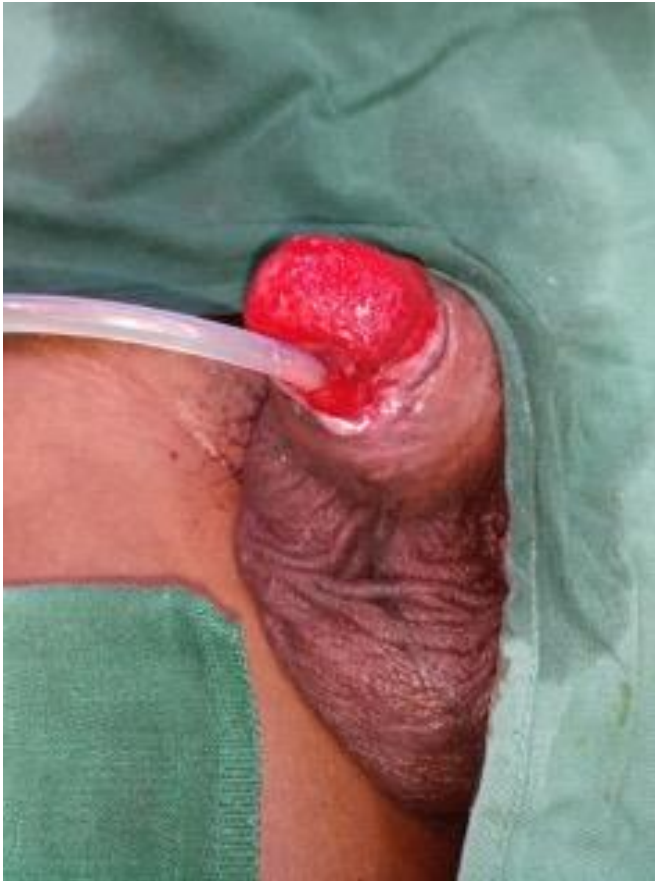

Figure 5. Penile Gland after losing the glans and skin with good granulation tissue

At exploration, hematoma was noted and evacuated. The anastomoses were all intact. The patient was taken back to the wards where monitoring and treatment continued. Darkening of the glans and skin was noted on post-operative day 5, and we decided to let it demarcate. We debrided on post-operative day 17, losing the glans and skin of the penis. The wound was cleaned and dressed until good granulation was achieved (Figure 5). Notably, the patient had also developed hypospadias (Figure 5).

Split-thickness skin grafting was done with 100% take (Figure 6).

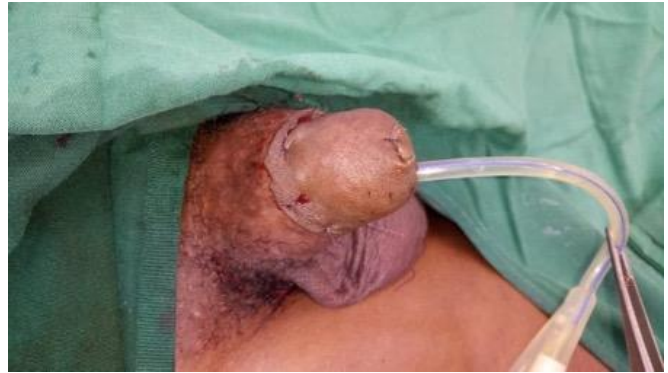

Figure 6. Post skin grafting.

At 6 months post-replantation, the patient has 7cm of erect penile gland and reported good sensation at the tip (Figures 7 and 8). The main complication reported at 6 months was hypospadias, causing a spraying urinary stream.

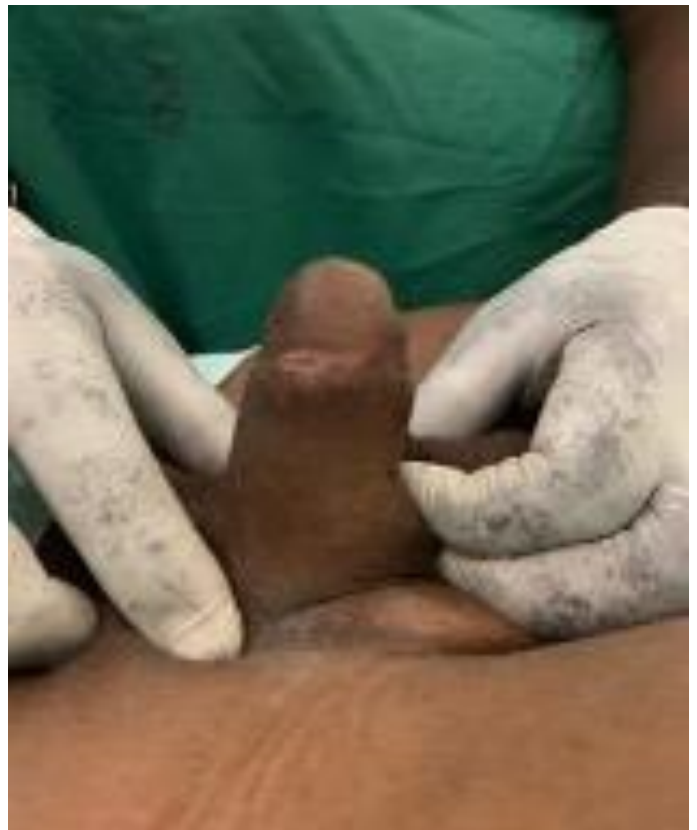

Figure 7. Well Healed Penile Gland Post Replantation

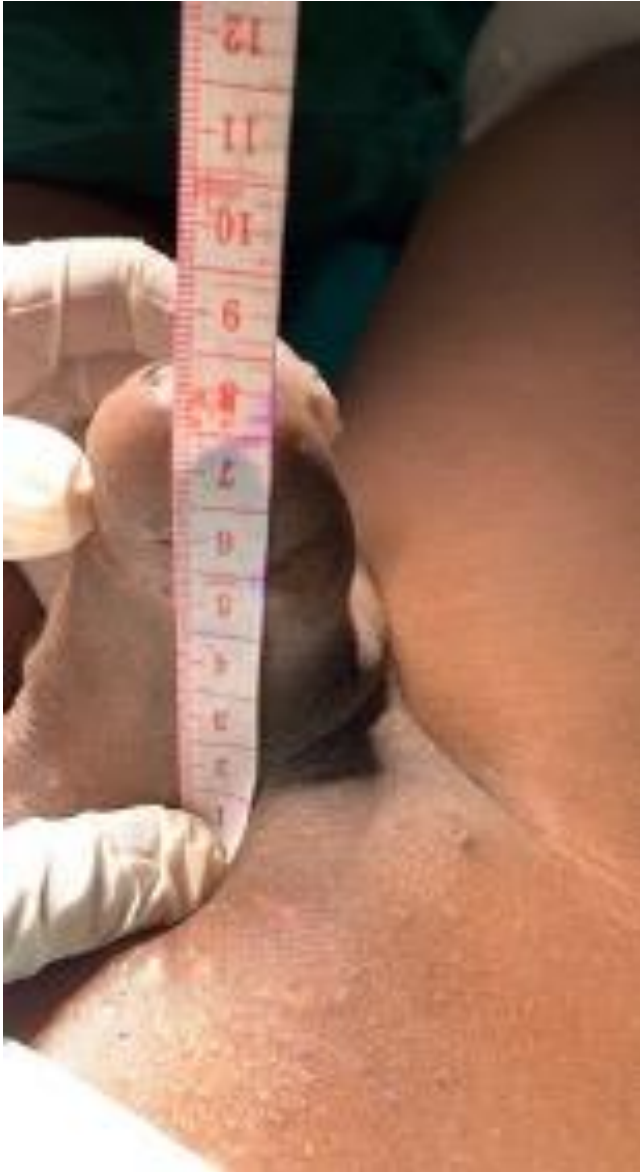

Figure 8. Erect Penile Gland post replantation

Discussion

The evolution of penile replantation has come a long way since the first reported case by Ehrlich in 1929 (6) to the first successful reports of microsurgical penile replantation by Tamai et al. (7) and Cohen et al. in 1977 (8). Prior to this, replantation was mainly done as a graft, or reconstructive options were offered to the patient. Engelman et al. (9) reported their experience with two cases and proposed that microsurgical replantation be the most ideal option for managing these patients, being superior to other plastic surgery reconstructive options. As advances in microsurgical

techniques continue, outcomes keep improving, but complications still occur.

Published data are case reports supporting the rarity of replantation (2,4). In our setting, the main cause of penile amputation is assault by spouse, and the main challenge we always face is that the amputated part is usually thrown away and patients present without it; this is also seen in many other settings in developing countries like ours (2,4). Our patient presented to us and had taken all the necessary precautions to preserve the amputated part.

One of the challenges we face in the third world is the lack of knowledge on how to preserve the amputated part; furthermore, ice may not be readily available. Another challenge is crushing of the vessels with instruments prior to referral for hemostasis, as seen with our case, which led to shortening of the vessels. The superficial vein was unsalvageable, and this is one of the postulated reasons for the congestion and loss of skin and the glans in our case. The other challenge in our setting is the lack of a microscope; we used loupe magnification 3.5× for the assistants and 4.5× and 7× for the surgeons, as was done by El Harrech et al. (10) in their cases.

Microsurgical neurovascular replantation offers the best outcomes in penile replantation compared with non-microvascular repair in terms of erectile function, return of sensation, aesthetics, and complications (11). Even with the best microsurgical technique, complications still arise, as in our case, which we re-explored, and despite the anastomosis being patent, complications still occurred, as was experienced by Landström et al. (5) in their literature review. Some of our complications of skin necrosis and loss of the glans were also seen by Wyczółkowski et al. (12). Most literature reports burying of the granulated penis in the scrotum, but in our case, we performed a thick split-thickness skin graft without complication of contraction (9,12). The patients also had hypospadias as a complication, as opposed to the strictures and fistulas that have been commonly reported (12).

Conclusion

Despite the challenges we face in our settings, microsurgical replantation remains an ideal option. The higher the volume a center does, the better the outcomes; nonetheless complications still occur, and it is important to discuss this with your patient. Education of both patients and primary care physicians improves outcomes, as in our case, with the amputated part preserved well by the patient's next of kin. collectively for the systemic component of the disease.

Declaration of interests

The authors declare no conflict of interest.

Author contributions

AK led in writing the original draft. All other authors contributed to editing and reviewing the manuscript.

References

1. Schweitzer I. Genital self-amputation and the Klingsor syndrome. *Aust N Z J Psychiatry*. 1990;24(4):566-9.
2. Mensah JE, Bray LD, Akpakli E, et al. Successful penile reimplantation and systematic review of world literature. *Afr J Urol*. 2017;23(3):253-7.
3. Tambo FFM. [Circumcision accidents in Yaoundé, Cameroon: a report on five cases]. *ProgrUrol*. 2012;22:63-6.
4. Bowa K, Phiri P. Iatrogenic penile amputation: an anatomy lesson. *East Cent Afr J Surg*. 2005;10(2):74-6.
5. Landströmlsson. East Cent Afr J Surg. 2005;10(2):74on: a report on five cases]. *ProgrJ Urol*. 2017physicians improves outcomes, as in our case-55.
6. Ehrlich WS. Two unusual penile injuries. *J Urol*. 1929;21(2):239-41.
7. Tamai S, Nakamura Y, Motomiya Y. Microsurgical replantation of a completely amputated penis and scrotum: case report. *Plast Reconstr Surg*. 1977;60(2):287-91.
8. Cohen BE, May JW, Daly JS et al. Successful clinical replantation of an amputated penis by microvascular repair. Case report. *Plast Reconstr Surg*. 1977;59(2):276-80.
9. Engelman ER, Polito G, Perley J et al. Traumatic amputation of the penis. *J Urol*. 1974;112(6):774-8.
10. El Harrech Y, Abaka N, Ghoundale O et al. Genital self-amputation or the Klingsor syndrome: Successful non-microsurgical penile replantation. *Urol Ann*. 2013;5(4):305-8.
11. Biswas G. Technical considerations and outcomes in penile replantation. *Semin Plast Surg*. 2013;27(4):205-10.
12. WyczWycz5 Technical considerations a, et al. Successfully performed reanastomosis of a completely amputated penis: surgical technique. *Urotoday Int J*. 2009;02.