

refractive status can be measured by refraction, keratometry, and corneal topography (2). A proposed mechanism explaining the distortions in refractive state of the cornea of an eye with pterygium, particularly astigmatism, is the traction forces of the contractile elements within the pterygium causing mechanical distortion and flattening of the cornea in its horizontal meridian, more frequently leading to hypermetropic with-the-rule astigmatism and localized pooling of tears at the advancing edge-head of the pterygium causing corneal flattening (3). Mohammed-Salih and Sharif (4) have reported against-the-rule and oblique types of astigmatism resulting from pterygial invasion of the cornea.

Pterygium excision surgery is therefore indicated when the lesion is progressive, threatening the visual axis to cause visual impairment, inducing diplopia due to extreme fibrosis, before surface ablative corneal refractive procedures, and for cosmetic reasons (5). Early or late surgical intervention leads to a reduction in astigmatism, which leads to significant improvement in vision consisting of gains in visual acuity and improved corneal topographic changes (6).

This study sought to demonstrate the visual significance of pterygium excision by analyzing for changes in visual acuity following changes in corneal astigmatism after pterygium excision surgery.

To the best of our knowledge, there has been no study in Ghana and in West Africa analyzing and quantifying the improvement in astigmatism and visual acuity after pterygium excision with conjunctival autograft (CAG). Additionally, pterygium excision with CAG, which is believed to have many advantages by studies from foreign populations, needs the said positive outcomes to be proven with local data.

Materials and methods

This study was a prospective, multi-centered, hospital-based, interventional study carried out from January 2017 to January 2018 at the district hospitals of Offinso and Juaben and at the Eye Centre of Komfo Anokye Teaching Hospital (KATH) in the Kumasi metropolis, Ashanti region, Ghana. Of the 137 patients operated within the study period in the participating facilities, 100

were enrolled. The criteria for inclusion were adult age (≥ 18 years), with primary pterygium, absence of major systemic illness, absence of ocular comorbidity, with written consent for surgery, and commitment to follow-up.

Two senior ophthalmologists who were trained on the preferred technique of surgery prescribed by the study protocol and the follow-up schedule performed all the surgeries, with one operating in both KATH and Juaben and the other operating in Offinso. Two ophthalmology residents in KATH and two optometrists, one each from Offinso and Juaben, were also oriented about on the study protocol in order to assist in data collection.

Face-to-face interview for patients' demographics was conducted followed by detailed pre-operative clinical examination by ophthalmologists. The examinations included uncorrected visual acuity (UVA) and corrected distance (aided) visual acuity (AVA) using Snellen's test charts at 6 m, slit-lamp examination, keratometry readings (K-readings) using Righton autorefractometer (Retinomax K-plus3 RDA 15200; Right Manufacturing Company Ltd, Tokyo, Japan), and dilated fundus examination. The extent of corneal invasion by pterygium was measured with calipers intraoperatively and added to the aforementioned data. Pterygium was classified into three grades depending on the extent of corneal encroachment: grade 1, extends < 2 mm on the cornea; grade 2, involvement of 2-4 mm of the cornea; grade 3, involvement of > 4 mm of the cornea but not involving the visual axis. This simple grading system was modified and adapted for this study from a system used in several similar studies in the published literature (4, 7-9).

Corneal astigmatism was determined as the difference between the K-reading values of the two principal corneal meridians of each participant's eye before and after surgery. All K-readings obtained were approximated to the nearest measurable two decimal place diopter (D) value. Differences in mean corneal astigmatism for before and after surgery were subjected to paired t-test statistics ($P < 0.05$) for statistical significance.

Both UVA and AVA were categorized into normal, mild, moderate, or severe impairment according to the current World Health Organization classification of visual impairment (10): normal, presenting visual acuity 6/5 to 6/12; mild, presenting visual acuity worse than 6/12; moderate, presenting visual acuity worse than 6/18; severe, presenting visual acuity worse than 6/60; blindness, presenting visual acuity worse than 3/60.

Chi-square test was used to ascertain the statistical significance of differences in numbers of eyes in categories of visual acuity before and after surgery. This was done at 1 day, 2 weeks, and 6 weeks post-operatively. A P-value <0.05 was considered statistically significant.

Surgical procedure

All surgeries were performed by two ophthalmologists with >3 years of post-qualification experience. Excision with extended tenon dissection and CAG method was used, and operating microscope was used in all surgeries. Retrobulbar injection of 4 mL of 2% xylocaine mixed with 1:100,000 epinephrine was given for anesthesia and akinesia with aseptic precautions. Eyes marked for surgery were painted with 10% povidone iodine, draped, and speculum passed. The conjunctival tissue over the body of the pterygium to be excised was marked, and the extent of corneal invasion of the pterygium was measured with calipers (Figure 1). Corneal invasion was taken as the length from the limbus to the cap of the pterygium. Sharp dissection of the superficial layers of the body of the pterygium following the initial markings was performed. This was followed by blunt dissection of the deep layers to separate the body of the pterygium from the underlying sclera and surrounding conjunctiva. The body of the pterygium, along with the underlying and at least 5 mm of adjacent tenons, was then completely excised using blunt-tipped Westcott scissors. The wound bed was cleaned of any remnant tenon tissue with Vannas scissors, and bleeding vessels were cauterized using wet-field cautery.

Pterygial tissue over the cornea was peeled and scraped clean with Colibri forceps and crescent blade, respectively.

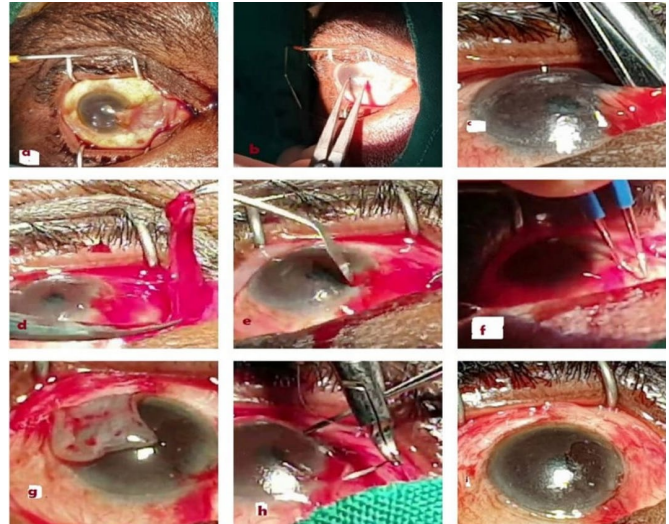


Figure 1. Surgical steps. (a) Wire speculum inserted to expose the natal pterygium. (b) Extent of corneal involvement measured with calipers (from the limbus to the cap). (c) Dissection of the body of the pterygium from the sclera. (d) Extended dissection and excision of the tenons. (e) The head of the pterygium was scraped off the cornea with a crescent blade. (f) Application of wet-field cautery. (g) Harvesting of the superotemporal conjunctival autograft (CAG). (h) CAG being secured with 10-0 Vicryl suture. (i) End of surgery.

The CAG was then harvested from the superotemporal conjunctiva after caliper measurements to ensure good fit for the recipient bare scleral site. Grafts were secured with 10-0 Vicryl sutures, and eyes were patched with 5% povidone iodine overnight.

Post-operative care and follow-up

All post-operative day 1 reviews were performed by the operating ophthalmic surgeons. Subsequent reviews were performed either by an ophthalmologist or an optometrist. Compliance to follow-up was ensured by calling patients by telephone a day before their review appointment dates. All patients were followed up for a minimum of 3 months post-operatively before discharge from clinical care.

On post-operative day 1, operated eyes were cleaned after patch removal, and their visual acuities checked by ophthalmic nurses. On occasions when the results of visual acuity testing were doubtful, study ophthalmologists cross-checked by repeating the tests themselves. Slit-lamp examination by ophthalmologists

followed the assessment for intactness of sutures and graft, clarity of area of the cornea involved, and cleanliness of site from where the graft was harvested. Patients were then prescribed steroid antibiotic eye drops (dexamethasone 1 mg+neomycin sulfate 3.5 mg+polymyxin B sulfate 6000 U) every 4 hours for 2 weeks and lubricating eye drops (1% w/v carboxymethylcellulose) every 2 hours, for surface lubrication, pain, and inflammation control.

Two weeks after surgery (see appearance of the eye in Figure 2), all patients were reviewed again, and slit-lamp examination, presenting visual acuity testing using the Snellen’s chart at 6 m, and recording of complications, if present, were done.

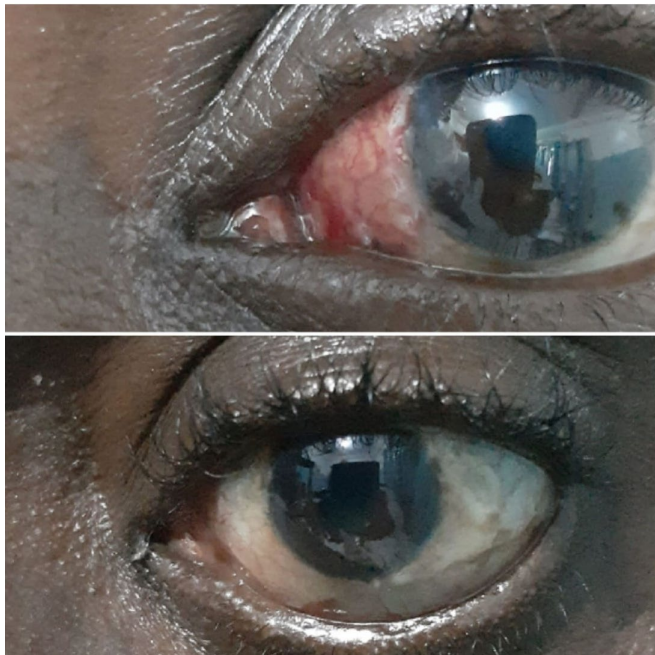


Figure 2. Photograph of the left eye post-terygium excision+conjunctival autograft. (top) Post-operative week 2. (bottom) Post-operative week 6.

In addition, K-readings, autorefraction, and subjective refraction (for best-corrected visual acuity) were done, and the findings were recorded. Tapering of topical steroid-antibiotic eye drops was also started on this visit for eyes that were found to have no complication.

The review on post-operative week 6 followed the same process as week 2 (see appearance of the eye in Figure 2). All subsequent reviews until patients’ discharge were treated as routine, with no data capturing for the study, but they were performed by the same surgeons or

optometrists working with surgeons, as done during the period of data collection.

Ethical approval (referenced CHRPE/AP/006/17) was sought from the Committee on Human Research, Publications, and Ethics of KATH/Kwame Nkrumah University of Science and Technology, after a mandatory registration of study with the Research and Development Unit of KATH. Data collection was started thereafter. This study was done following ethical principles described in the Declaration of Helsinki (11). Patients were informed about the duration and frequency of follow-up. Written informed consent was then obtained.

Results

One hundred eyes of 100 patients (females, n=65, 65%; males, n=35, 35%; mean age, 47.1±11.5 years; range, 23-76 years) were enrolled within the period of study, of whom 77 were enrolled in KATH, 13 in Juaben, and 10 in Offinso. All were primary pterygia. Forty-four percent of the participants were unemployed, 9% were artisans, 9% were farmers, 6% were menial workers, 17% were traders, and 15% were public sector workers. No intraoperative or post-operative complications were observed.

Table 1. Distribution of astigmatism among participants

Astigmatism (d)	Pre-operative	Post-operative week 2	Post-operative week 6
0.00-0.99	24 (24.0)	37 (37.0)	40 (40.0)
1.00-1.99	21 (21.0)	36 (36.0)	42 (42.0)
2.00-2.99	8 (8.0)	10 (10.0)	9 (9.0)
3.00-3.99	4 (4.0)	9 (9.0)	5 (5.0)
4.00-4.99	4 (4.0)	4 (4.0)	4 (4.0)
≥5.00	39 (39.0)	4 (4.0)	–
Total	100 (100.0)	100 (100.0)	100 (100.0)

Values are presented as number (percentage).

The number of eyes with a low range (<2.00 D) of astigmatism increased with longer post-operative period, whereas those with at least 5.00-D astigmatism decreased as the post-operative period advanced (Table 1). The pre-operative mean astigmatism of 5.00±5.9 D decreased to 1.7±1.5 D 2 weeks after surgery and to

1.3±1.0 D 6 weeks after surgery (Table 2), and the reductions were statistically significant (P<0.001) The reduction in mean astigmatism (0.40 D) between weeks 2 and 6 post-operatively was statistically significant (P<0.001) (Table 2).

Table 2. Change in mean astigmatism after surgery

	ASTIGMATISM (D), MEAN±SD	95% CI	P VALUE
Pre-operative	5.00±5.9	3.8-6.2	<0.001
Post-operative week 2	1.70±1.5	1.4-2.0	<0.001
Post-operative week 6	1.30±1.0	1.1-1.5	<0.001

Paired t-test, P<0.05 is statistically significant. SD, standard deviation; CI, confidence interval.

Discussion

The demographic characteristics of patients in this study are quite similar to studies from Ghana and other similar geographic locations (12). The mean age of 47.1 years is comparable with those reported by Kumah et al. (12) and Essuman et al. (13) (41.4 and 45.6 years, respectively). The relationship between pterygium prevalence and occupation is well established in the published literature (12). This study found a good mix of participants with varying occupations though 44% had no employment. The consensus that outdoor work (a surrogate for solar UV exposure) is a risk factor for pterygium development has been supported by this study (14). Close to a third (30.34%) of participants who

had employment were traders. The majority of these traders work in open-air markets due to economic reasons and they can be hypothetically said to get more exposed to the sun’s radiations increasing their risk for the development of pterygium.

The number of eyes with a low range of astigmatism increased with an increased post-operative period while those with at least 5.00 D astigmatism decreased with the passing post-operative days. This corroborated the trend in reduction in mean astigmatism following surgery in this study. The pre-operative mean astigmatism of 5.00 D for enrolled eyes reduced progressively and significantly to 1.30 D 6 weeks after surgery. Makkar et al. reported a mean improvement of 0.18 D for 20 eyes, but the follow-up period was 3 months and excision was done with an amniotic membrane graft (15). Altan-Yaycioglu et al. (9) also reported of astigmatic values decreasing from 3.47±2.50 to 1.29±1.07 D (P < 0.001) following surgery in 240 Turkish eyes.

In a hospital-based prospective interventional study to determine the effect of pterygium excision on the degree of corneal induced astigmatism and visual acuity, the mean pre- and post-operative astigmatism values were 2.12±1.09 and 0.72±0.50 diopter cylinder, respectively (P<0.001) (16).

Table 3. Distribution of preoperative and postoperative unaided visual acuity

Static visual acuity	Visual acuity				Total	P-value
	NORMAL	MILD	MODERATE	SEVERE		
Pre-operative	77	10	11	2	100	0.241
Post-operative day 1	64	13	20	2	99*	
Pre-operative	77	10	11	2	100	0.012
Post-operative week 2	91	7	2	0	100	
Pre-operative	77	10	11	2	100	0.009
Post-operative week 6	93	4	3	0	100	

Chi-square test.

*Visual acuity for one participant was not captured.

Normal, presenting visual acuity 6/5 to 6/12; mild, presenting visual acuity worse than 6/12; moderate, presenting visual acuity worse than 6/18; severe, presenting visual acuity worse than 6/60) (10).

Table 4. Distribution of preoperative and postoperative aided visual acuity*
Chi-square test.

Static visual acuity	Visual acuity				Total	P-value
	Normal	Mild	Moderate	Severe		
Pre-operative	89	3	7	1	100	0.009
Post-operative day 1	69	10	18	2	99	
Pre-operative	89	3	7	1	100	0.091
Post-operative week 2	96	3	1	0	100	
Pre-operative	89	3	7	1	100	0.092
Post-operative week 6	97	2	1	0	100	

*Aided visual acuity, visual acuity with pinhole for post-operative day 1 and refraction outcomes for weeks 2 and 6.

Normal, presenting visual acuity 6/5 to 6/12; mild, presenting visual acuity worse than 6/12; moderate, presenting visual acuity worse than 6/18; severe, presenting visual acuity worse than 6/60 (10).

Table 5. Distribution of normal visual acuity (Snellen visual acuity converted to logMAR) pre- and post-operatively

Visual acuity	Min	Mean	Sd	Max	N
Pre-operative					
Unaided	-0.41	0.20	0.34	0.69	77
Aided	-0.41	0.11	0.31	0.69	89
Post-operative day 1					
Unaided	0.00	0.33	0.27	0.69	69
Aided	0.00	0.31	0.27	0.69	69
Post-operative week 2					
Unaided	-0.41	0.23	0.33	0.69	91
Aided	-0.41	0.10	0.29	0.69	93
Post-operative week 6					
Unaided	-0.41	0.13	0.28	0.69	96
Aided	-0.41	0.02	0.26	0.69	97

The follow-up period was the same as in this study, but only 45 eyes were enrolled. Pterygium is known to cause irritation, redness, ocular surface inflammation, and tear film instability. The complaints result from induced astigmatism or are due to direct invasion of the visual axis by advancing growths. The flattening of the cornea in the horizontal meridian causes induced, with-the-rule, oblique, and sometimes irregular corneal astigmatism

Similar finding has been reported in the published literature (17). In a prospective study to determine the

(17). Any refractive visual impairment associated with pterygium can stabilize 6 weeks after surgery, and this was observed in this study (18). The improvement in both UVA and AVA after surgery was demonstrated as improvement in both number of eyes with Snellen’s normal visual acuity and mean logMAR visual acuity (Tables 3, 4, and 5).

visual outcome and efficacy of pterygium excision with CAG involving 25 eyes followed up for 6 months, Bhandari et al. found that UVA and AVA improved by

one or two lines in all eyes treated (19). Outcomes from a similarly designed study from Bulgaria by Zheleva and Voynov (17) showed that the mean UVA pre-operatively improved by 0.02 logMAR units 3 months after surgery, and the mean BCVA (best-corrected visual acuity) before surgery also improved by 0.02 logMAR units after the procedure. This study showed bigger logMAR unit improvements in both UVA and (0.07) and AVA (0.09), which were statistically significant.

The observed reduction in the number of eyes with normal visual acuity and mean logMAR visual acuity day 1 after surgery (Tables 3, 4, and 5) was attributable to intense irritation from suture ends, conjunctival inflammation from surgical trauma and incomplete re-epithelialization of the cornea with photophobia on day 1 after the surgery.

This study has some limitations. The contribution to the enhancement in visual acuities as a result of improvement in other conditions such as dry eyes was not considered in this study. The follow-up period (6 weeks) after surgery is too short to allow detection of all the potential outcomes of surgery, and this, to some extent, limits the external extrapolation of this study's findings. Caliper measurement of extent of corneal encroachment intra-operatively might not have been as accurate as pre-operative measurement by slit-lamp photography with digital measurements, as done by Lin and Stern (20). Visual acuity assessment with Snellen's chart instead of the logMAR chart for this study means less accuracy in the categorization of visual acuity, with possible dilemmas in the placement of some scores of visual acuities. Lack of wavefront analysis for all the possible vision-disturbing aberrations associated with pterygium induced corneal distortion in a study like this is a remarkable weakness.

Conclusion

This study shows that pterygium excision with CAG leads to significant improvement in best-corrected visual acuity 6 weeks post-operatively. Pterygia excision with CAG leads to an approximately fourfold reduction in

mean pterygium-induced astigmatism by 6 weeks post-operatively.

Author contribution

Amoah, Kwadwo

Conceptualization (Equal); Data curation (Equal); Investigation (Equal); Project administration (Equal); Writing – original draft (Equal)

Mohammed, Abdul-Kabir

Methodology (Equal); Writing – original draft (Equal)

Lartey, Seth Yaw

Supervision (Equal); Writing – review & editing (Equal)

Ahmed, Abdul-Sadik

Data curation (Equal); Methodology (Equal)

Nyan Arthur, Kwesi Amissah

Formal analysis (Equal); Resources (Equal); Supervision (Equal)

Kyei, Ernest Nkansah

Methodology (Equal); Writing – original draft (Equal)

References

1. Zigman S. Visual significance of yellow optical filters. In: Holick M.F. (eds) *Biologic Effects of Light* 2001. Boston, MA: Springer; 2002. pp. 83-6.
2. Yagmur M, Özcan AA, Sari S, et al. Visual acuity and corneal topographic changes related with pterygium surgery. *J Refract Surg.* 2005; 21: 166-70.
3. Maheshwari S. Effect of pterygium excision on pterygium induced astigmatism. *Indian J Ophthalmol.* 2003; 51: 187.
4. Mohammad-Salih PA, Sharif AFM. Analysis of pterygium size and induced corneal astigmatism. *Cornea.* 2008; 27: 434-8.
5. O'Brart DP, Williams K. Pterygium after hyperopic laser-assisted sub-epithelial keratomileusis (LASEK). *Clin Exp Optom.* 2013; 96: 336-8.
6. Bahar I, Loya N, Weinberger D, et al. Effect of pterygium surgery on corneal topography: a prospective study. *Cornea.* 2004; 23: 113-7.
7. Parajuli R, Bajracharya L. Changes in astigmatism before and after pterygium surgery. *Birat J Health Sci.* 2019; 4: 596-601.
8. Devika P, Lakshmi K, Rajani K, et al. Astigmatism in primary pterygium and its effect on visual acuity. *J Evid Based Med Healthc.* 2015; 2: 6036-40.
9. Altan-Yaycioglu R, Kucukerdonmez C, Karalezli A, et al. Astigmatic changes following pterygium removal: comparison of 5 different methods. *Indian J Ophthalmol.* 2013; 61: 104.
10. World Health Organization. Vision impairment and blindness. Available at <https://www.who.int/news-room/fact->

- sheets/detail/blindness-and-visual-impairment. Accessed June 28, 2019.
11. Association WM. World Medical Association Declaration of Helsinki: ethical principles for medical research involving human subjects. *JAMA*. 2013; 310: 2191-4.
 12. Kumah D, Oteng-Amoako A, Apio H. Prevalence of pterygium among kitchen staff in senior high schools in the Kumasi metropolis, Ghana. *Ghana J Sci*. 2011; 13: 83-8.
 13. Essuman V, Ntim-Amponsah C, Vemuganti G, et al. Epidemiology and recurrence rate of pterygium post excision in Ghanaians. *Ghana Med J*. 2014; 48: 39-42.
 14. Modenese A, Gobba F. Occupational exposure to solar radiation at different latitudes and pterygium: a systematic review of the last 10 years of scientific literature. *Int J Environ Res Public Health*. 2018; 15: 37.
 15. Makkar B, Agrawal I, Ahuja A, et al. Comparison of preoperative and postoperative astigmatism following pterygium excision with conventional conjunctival graft and amniotic membrane graft. *Sch J Appl Med Sci*. 2015; 3: 1477-82.
 16. Lawan A, Hassan S, Ifeanyichukwu EP, et al. The astigmatic effect of pterygium in a tertiary hospital in Kano, Nigeria. *Ann Afr Med*. 2018; 17: 7.
 17. Zheleva V, Voynov L. Comparative study of astigmatic changes following pterygium excision with conjunctival autograft transplantation. *Biotechnol Biotechnol Equip*. 2018; 32: 433-6.
 18. Maheshwari S. Pterygium-induced corneal refractive changes. *Indian J Ophthalmol*. 2007; 55: 383.
 19. Bhandari V, Rao CL, Ganesh S, et al. Visual outcome and efficacy of conjunctival autograft, harvested from the body of pterygium in pterygium excision. *Clin Ophthalmol (Auckland, NZ)*. 2015; 9: 2285.
 20. Stern GA, Lin A. Effect of pterygium excision on induced corneal topographic abnormalities. *Cornea*. 1998;17(1):23-27.